

## Abnormal right heart filling after cardiac surgery: time course and mechanisms

Bengt Wranne, Fausto J Pinto, Eskil Hammarström, Frederick G St Goar, Josephine Puryear, Richard L Popp

### Abstract

**Objective**—To study the time course and underlying mechanisms of right heart filling after cardiac surgery.

**Design**—A prospective observational study of adult patients undergoing cardiac surgery.

**Setting**—Echocardiography laboratory of the Stanford University Medical Center.

**Patients**—Twenty six patients (mean age 54.9) undergoing cardiac surgery were studied before and two days, one week, six weeks, and six months after cardiac surgery.

**Main outcome measures**—Flow in the hepatic veins and superior vena cava, tricuspid and mitral annulus motion, signs of tricuspid regurgitation, and right ventricular size were assessed by echocardiography.

**Results**—Right heart filling, expressed as the ratio of systolic to diastolic forward flow Doppler velocity integrals in the superior vena cava and by tricuspid annulus motion, decreased in parallel from before surgery baseline values of 3.5 (SD 3.1) and 21.9 (3.4) mm, respectively to 0.2 (0.1) and 8.1 (2.3) mm two days after operation. A gradual increase towards baseline values was noted after six months, to 1.4 (1.3) and 15.1 (2.3) mm respectively; however, these values were still significantly less than those before operation. Similar changes were seen in the hepatic venous flow pattern. The decrease in total tricuspid annulus motion was most pronounced in its lateral segment and the atrial component of the tricuspid annulus motion showed similar changes.

**Conclusions**—The pronounced decrease in tricuspid annulus motion during the early postoperative period suggests right atrial and right ventricular dysfunction as mechanisms responsible for the early changes seen. The progressive return to a normal venous filling pattern and the partial recovery of annular motion six months after operation further support the influence of the above mechanisms, as well as their resolution with time. The persistent flow abnormalities and compromised motion of the free aspects of the tricuspid annulus, however, suggest long term tethering of the right heart wall.

Right heart filling, reflected in the pattern of systemic venous return, becomes abnormal in patients who undergo cardiac surgery supported by cardiopulmonary bypass.<sup>1-3</sup> These changes were first described as an alteration in jugular venous pulse contours and flow velocities from the normal dominant systolic flow to an equal or dominant diastolic flow.<sup>4,5</sup> Recently we have shown, using intraoperative transoesophageal echocardiography, that the venous flow pattern is normal before cardiopulmonary bypass even with the pericardium fully opened, but becomes abnormal immediately after termination of cardiopulmonary bypass.<sup>6</sup> A mechanical impediment to cardiac motion and a combination of abnormalities in right heart function were suggested as possible mechanisms for these changes immediately after cardiopulmonary bypass. The present study was undertaken to further elucidate the time course and underlying mechanisms of these changes through repeated observations before and during a six month period after operation.

### Patients and methods

#### PATIENT POPULATION

We studied 26 patients (mean age 54.9, range 20-80 years; 16 men and 10 women) undergoing their first cardiac surgery. Sixteen patients had coronary artery bypass grafts (one also had mitral valve replacement and two had aortic valve replacement), two had aortic valve and four mitral valve replacement or repair, and four had ablative surgery of accessory bundles. All patients were in sinus rhythm at the time of preoperative study and none had clinical signs of right heart failure. Sixteen patients in the present study were also included in the recently reported intraoperative study.<sup>6</sup> All subjects gave informed written consent to the protocol, which was approved by the Committee for the Protection of Human Subjects at the Stanford University Medical Center.

#### ANAESTHESIA

High dose narcotics with benzodiazepine and non-depolarising muscle relaxants were used to induce and maintain general anaesthesia. Eight patients received 0.3 to 0.6% isoflurane, and four received 0.2% halothane, for part of the prebypass period. These agents were typically used to blunt or prevent hyperdynamic responses associated with the initial surgical incision, median sternotomy, or aortic

Cardiology Division,  
Stanford University  
School of Medicine,  
Stanford, California,  
USA

B Wranne  
F J Pinto  
E Hammarström  
F G St Goar  
J Puryear  
R L Popp

Correspondence to  
Dr Richard L Popp,  
Division of Cardiology,  
Stanford University School  
of Medicine, Stanford,  
CA 94305, USA.

Accepted for publication  
2 May 1991

cannulation. No patient received a volatile anaesthetic after cardiopulmonary bypass was completed. Patients were mechanically ventilated with a mixture of oxygen and nitrogen. Haemodynamic control was accomplished with glyceryl trinitrate, nitroprusside, dopamine, dobutamine, adrenaline and/or isoprenaline.

The following factors related to anaesthesia or surgery were analysed: cardiopulmonary bypass and aortic cross clamp time, type of cardioplegia, type of anaesthetic, and need and use of inotropic agents to maintain adequate cardiac output immediately after bypass.

#### SURGERY

After midline sternotomy, the pericardium was opened and the right atrium and ascending aorta were cannulated. Cardiopulmonary bypass was started after administration of cold myocardial preservation solution into the aortic root or directly into the coronary arteries in 22 patients (1288 (849) ml, range 500–

3200 ml). No cardioplegia was used in four patients. Mean total time of cardiopulmonary bypass was 123 (38) min and mean aortic cross clamp time was 71 (29) min. Mean bladder temperature was 29.0 (2.2)°C. At the end of operation the pericardium was left open in all patients. The chest was closed after placement of two or more chest tubes for drainage.

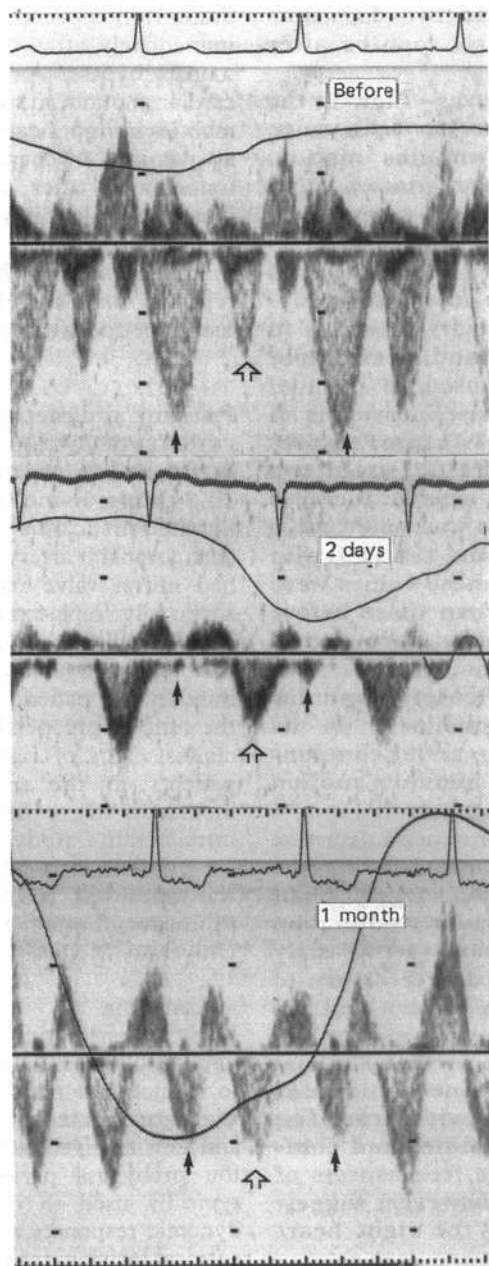
#### ECHOCARDIOGRAPHY

All ultrasound recordings were obtained with a Hewlett-Packard (Andover, MA) ultrasound phased array 77020 imaging system with a 2.5 or 3.5 MHz transducer. Pulsed wave Doppler echocardiographic recordings were obtained from the hepatic veins and superior vena cava as previously reported.<sup>7</sup> Anterograde flow through the tricuspid valve was measured by placing the Doppler sample volume at the tips of the tricuspid valve leaflets. Doppler colour flow mapping was used for semiquantitative assessment of valve regurgitation.<sup>8</sup> Tricuspid and mitral annulus motion were obtained at four different locations around the circumference of the annulus (lateral, medial, anterior, and posterior) by cross sectionally directed M mode as recently described.<sup>9</sup> Patients were examined at five different times: all patients before surgery; 17 patients two days (mean (SD) 1.8 (1.0), range 1–5); 22 patients seven days (mean 7.2 (1.9), range 5–12); 19 patients six weeks (mean 6.3 (3.1), range 4–15); and nine patients six months (means 6.5 (0.5), range 5–8) after surgery. During the first days after operation patients often felt uncomfortable; thus priority was given to obtain recordings of tricuspid annulus motion and hepatic venous flow. Flow in the superior vena cava was usually not obtained at the recording two days after operation due to soreness at the insertion site of the internal jugular venous cannula. Patients with atrial fibrillation or other arrhythmias after operation were excluded at that time, but were included on later occasions if sinus rhythm was restored.

#### ANALYSIS OF DOPPLER RECORDINGS

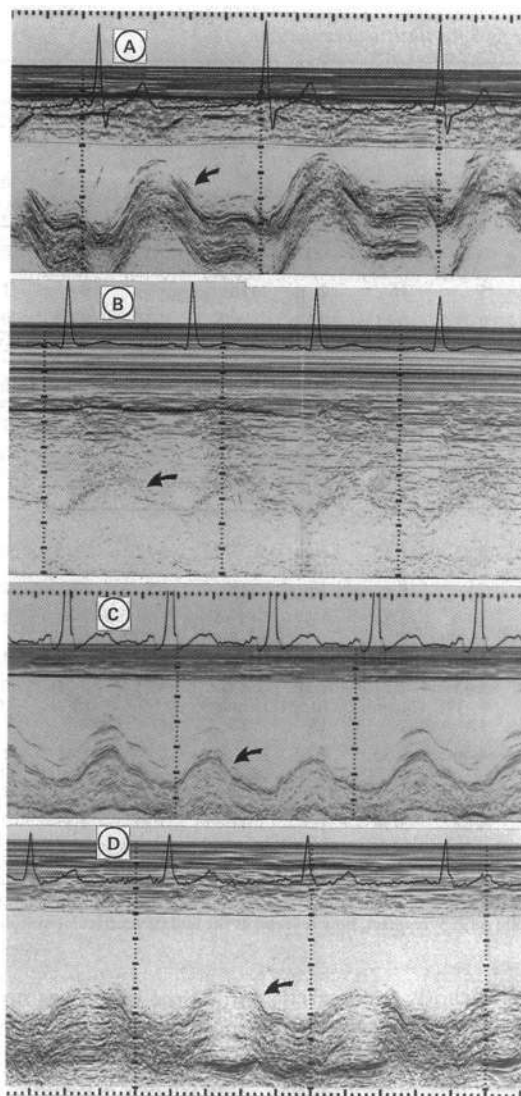
Hepatic venous flow and flow in the superior vena cava during each beat was analysed by dividing the cardiac cycle into systole and diastole.<sup>7</sup> Systole was defined as the interval from tricuspid valve closure to tricuspid valve opening, and diastole from tricuspid valve opening to tricuspid valve closure (fig 1). Tricuspid opening and closure were determined from the tricuspid anterograde flow on pulsed wave Doppler ultrasound recordings and were referenced to the electrocardiogram. Venous peak flow velocities and flow velocity integrals were measured in both systole and diastole. The integrals were measured by manual planimetry as an average of three heart beats in expiration, the breathing pattern being recorded by a nasal thermistor. Angle correction was never used. The time to reach peak flow velocity, both in systole and diastole, was also determined and corrected for heart rate.<sup>10</sup>

*Figure 1 Hepatic venous flow tracings from the same patient before (top panel), two days after (middle panel), and six weeks after surgery (bottom panel). Recordings show normal patterns before, reversed systolic to diastolic flow ratio two days after, and partial but not total return towards a normal pattern six weeks after surgery. Flow below the zero line is toward the heart. Black arrows indicate systolic flow and open arrows indicate diastolic flow. Simultaneous electrocardiogram and respiratory tracings are recorded. The respiratory tracing is displaced upwards with inspiration.*





**Figure 2** Cross sectionally guided M mode recordings of the motion of the lateral portion of tricuspid annulus (A) before, (B) two days after, (C) six weeks after, and (D) six months after surgery. Although the recorded signals do not appear identical, the same location was established by using cross sectional guidance at each time after surgery. Note the decrease in annulus amplitude in the postoperative tracings. Black arrows indicate tricuspid annulus.



#### ANALYSIS OF TRICUSPID AND MITRAL ANNULUS MOTION, TRICUSPID REGURGITATION, AND RIGHT VENTRICULAR AREA

Tricuspid and mitral annulus motion were measured at four different locations around the circumference for each annulus by cross sectionally guided M mode echocardiography.<sup>9</sup> For each location the maximal amplitude of motion and the atrial contribution were measured and the average of three to five beats reported (fig 2). Tricuspid regurgitation was assessed by Doppler colour flow mapping and, if present, classified according to the spatial distribution of the regurgitant jet within the right atrium: trace or mild regurgitation occupied less than one third of the atrium, moderate from one third to two thirds, and severe greater than two thirds of the atrium.<sup>8</sup> Patients served as their own controls for serial changes. All recordings were read by two investigators, who reached a consensus.

Right ventricular systolic (RVS) and diastolic (RVD) areas were measured by planimetry of the apical four chamber view, and the right ventricular area shortening fraction was calculated as  $(RVD - RVS)/RVD$ . All recordings were classified as excellent, good, fair, or poor according to image quality and right ventricular endocardial definition.

The data reported came from only the fair to excellent recordings. The average of three measured beats is presented.

#### DATA ANALYSIS

Values are expressed as mean (SD). Differences in mean values were compared by a two tailed paired Student's *t* test. Differences between stages were analysed by two way analysis of variance. For significant F ratios, group mean values were compared by Fisher's test. Correlations between heart rate, different intraoperative conditions, and changes in venous flow velocity integrals were determined by multiple regression analysis. The incidence of measurable tricuspid and mitral annulus atrial contribution and reversal of hepatic venous flow and flow in the superior vena cava were compared by the  $\chi^2$  test. Statistical significance was set at  $p < 0.05$ .

#### Results

##### SYSTEMIC VENOUS FLOW RECORDINGS

Before surgery a normal pattern of systemic venous flow with systolic predominance was seen in all patients (table 1). After operation there was a significant decrease in systolic and a significant increase in diastolic forward flow velocities; thus the systolic:diastolic ratio of peak flow velocities (2.0 (0.8) to 0.3 (0.2) m/s,  $p < 0.001$ ) and velocity integrals (3.5 (3.1) to 0.2 (0.1) cm,  $p < 0.001$ ) significantly decreased after surgery (figs 1 and 3, table 1). The shape of the envelope of the venous flow velocity curves changed after surgery, with a significantly earlier peak (corrected for heart rate) for systolic flow occurring 98 (55) ms after tricuspid valve closure after surgery, compared with 199 (144) ms before surgery ( $p < 0.001$ ). Values are given for flow in the superior vena cava but changes in hepatic venous flow were similar. Diastolic flow tended to peak later in relation to tricuspid opening after surgery (205 (159) ms) compared with that before surgery (160 (189) ms), but this difference was not statistically significant.

Hepatic "v" wave reversal was present in nine of 26 patients before surgery and was seen in all 16 patients studied soon after operation. Reversed flow coincident with atrial contraction was present in 15 of 26 patients before surgery. After surgery only six presented a discrete flow curve, whereas the others showed only a notch during diastolic filling (fig 4). All of these changes were more pronounced at the early observation two days after surgery and tended to normalise partially during the six month follow up period, though the systolic : diastolic ratios remained significantly lower than at the recording before surgery ( $p < 0.02$ ). Figure 1 shows typical curves from one patient.

##### ANNULUS MOTION

Tricuspid annulus motion was normal before operation in all patients,<sup>9</sup> with a significantly higher amplitude of motion in the lateral point than at other points ( $p < 0.002$ ), giving it a swinging or tilting motion with the hinge point at the septal margin. Soon after operation,

**Table 1** Peak flow velocities and flow velocity integrals in the hepatic vein and superior vena cava before and at four times after cardiac surgery. See fig 3 for statistical evaluation

		Systole		v reversal		Diastole		a reversal		Syst/Diast		
		HV	SVC	HV	SVC	HV	SVC	HV	SVC	HV	SVC	
Peak flow velocities (m/s)	Before	mean	0.33	0.41	0.14	0.11	0.18	0.22	0.19	0.13	2.1	2.0
		(SD)	(0.13)	(0.12)	(0.07)	(0.04)	(0.08)	(0.09)	(0.09)	(0.05)	(1.3)	(0.8)
		No	19	24	9	11	19	24	15	22	19	24
Two days		mean	0.06	0.11	0.12	0.17	0.25	0.37	0.09	0.30	0.3	0.3
		(SD)	(0.04)	(0.07)	(0.07)	(0.07)	(0.07)	(0.08)	(0.05)	(0.05)	(0.2)	(0.2)
		No	16	5	16	2	16	5	6	1	16	5
One week		mean	0.13	0.21	0.11	0.12	0.25	0.32	0.09	0.16	0.6	0.7
		(SD)	(0.07)	(0.08)	(0.05)	(0.07)	(0.09)	(0.11)	(0.05)	(0.05)	(0.4)	(0.3)
		No	18	18	17	13	18	18	11	12	18	18
Six weeks		mean	0.26	0.27	0.15	0.13	0.27	0.30	0.16	0.14	1.0	1.0
		(SD)	(0.14)	(0.07)	(0.07)	(0.07)	(0.11)	(0.11)	(0.06)	(0.06)	(0.4)	(0.6)
		No	18	20	12	16	18	20	9	15	18	20
Six months		mean	0.34	0.27	0.19	0.13	0.45	0.34	0.24	0.20	0.8	0.9
		(SD)	(0.14)	(0.09)	(0.12)	(0.05)	(0.18)	(0.20)	(0.13)	(0.07)	(0.1)	(0.4)
		No	4	9	4	9	4	9	4	6	4	9
Flow velocity integrals (cm)	Before	mean	7.88	8.83	1.35	0.99	3.70	3.77	2.28	0.94	2.9	3.5
		(SD)	(3.45)	(2.23)	(0.99)	(0.59)	(2.11)	(2.12)	(1.36)	(0.63)	(2.1)	(3.1)
		No	15	22	8	10	15	22	12	19	15	22
Two days		mean	1.04	1.30	1.30	1.37	5.34	7.24	0.66	1.91	0.2	0.2
		(SD)	(0.86)	(0.91)	(1.38)	(1.38)	(2.00)	(2.78)	(0.89)	(0.89)	(0.2)	(0.1)
		No	16	5	14	3	16	5	6	1	16	5
One week		mean	1.54	2.43	1.14	1.10	4.86	5.28	0.56	0.96	0.4	0.6
		(SD)	(1.10)	(1.35)	(0.86)	(0.55)	(2.42)	(1.93)	(0.91)	(0.89)	(0.4)	(0.4)
		No	18	17	16	13	18	17	9	13	18	17
Six weeks		mean	3.90	4.40	1.32	1.12	6.04	5.99	1.66	1.18	0.7	0.9
		(SD)	(2.78)	(1.78)	(0.74)	(0.77)	(4.52)	(2.68)	(1.03)	(0.52)	(0.4)	(0.8)
		No	17	19	12	16	17	19	9	13	17	19
Six months		mean	6.26	4.61	3.36	1.57	11.35	5.38	4.47	2.30	0.6	1.4
		(SD)	(2.62)	(2.70)	(2.82)	(0.80)	(5.36)	(3.05)	(3.89)	(1.79)	(0.1)	(1.3)
		No	4	9	4	9	4	9	4	7	4	9

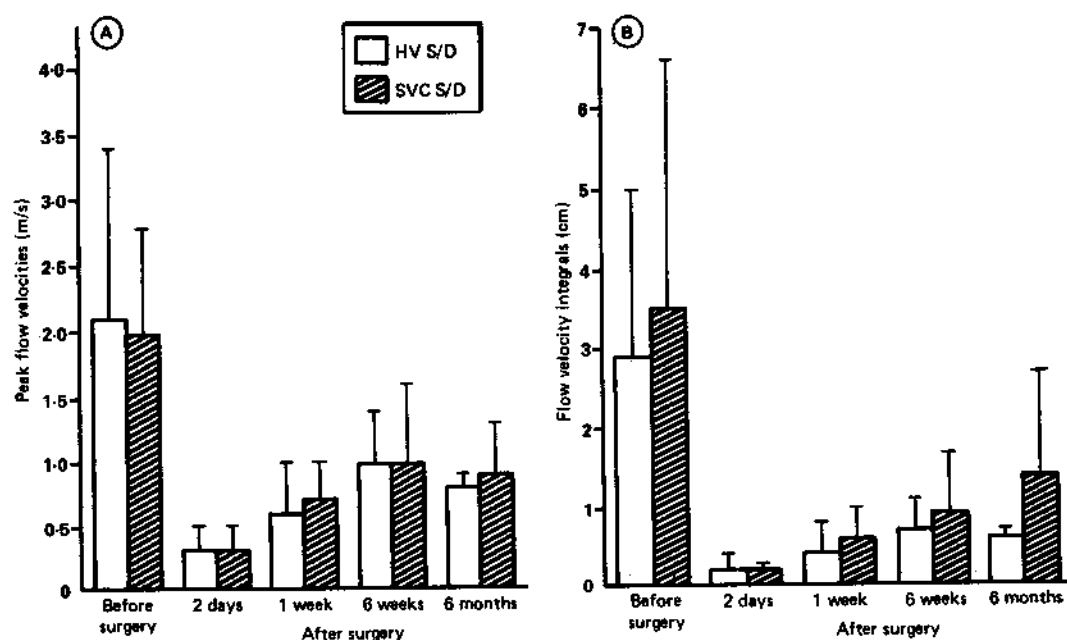
a reversal, flow reversal coincident with atrial contraction; HV, hepatic venous; No, number of observations; SVC, superior vena cava; Syst/Diast, systolic to diastolic ratio; v reversal, flow reversal at the end of ventricular systole.

annulus motion was significantly decreased ( $p < 0.001$ ), particularly in its lateral part, causing the ring to move more like a piston but with very low amplitude. The decrease in amplitude was most pronounced early after surgery and this tended to become normal with time. Six months after operation the amplitude of motion was still less than that before surgery for the anterior ( $p < 0.05$ ), lateral ( $p < 0.004$ ), and posterior parts ( $p < 0.001$ ), and the medial part had regained its baseline motion (NS). At

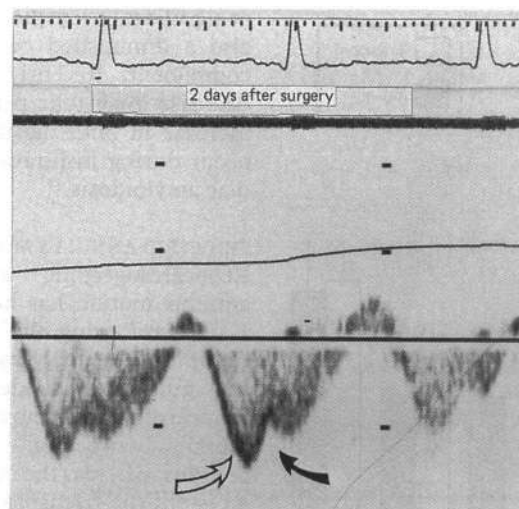
this time there was no significant difference in motion of the four tricuspid annulus points. Thus six months after surgery the annulus still moved like a piston. The tricuspid annulus a wave was usually easy to define before surgery and was seen in most patients (table 2). Two days to six weeks after surgery it was seen in only a few patients ( $p < 0.003$ ) compared with patients before surgery, but it was seen in all patients investigated six months after surgery.

Mitral annulus motion (table 2, fig 5) was

**Figure 3** Systolic/diastolic (S/D) peak flow velocity ratios and velocity time integral ratios in the hepatic vein (HV) and superior vena cava (SVC) (means (SD)) before and two days, one week, six weeks, and six months after cardiac surgery.



**Figure 4** Example of hepatic venous tracing after cardiac surgery with a predominant diastolic flow (open arrow) showing a discrete diastolic notch (black arrow) coincident with atrial contraction.



analysed in the group of patients without mitral valve surgery. Before surgery mitral annulus motion was significantly lower than tricuspid annulus motion ( $p < 0.001$ ), which is a normal finding,<sup>9</sup> but after surgery the motion amplitude of the two annuli was not significantly different. Mitral annulus waves were seen in most patients before surgery. A significant decrease in measurable waves was seen two days to six weeks after surgery ( $p < 0.04$ ). Measurable waves occurred significantly more often for the mitral than for the tricuspid annulus ( $p < 0.001$ ) during this period.

#### RIGHT VENTRICULAR AREA

Right ventricular systolic and diastolic areas, as well as the right ventricular area shortening fraction, did not change significantly between all five measuring times (55% before and 54% two days, 55% one week, 52% one month, and 48% six months after surgery; NS).

#### TRICUSPID REGURGITATION

Sixteen patients had trace or mild tricuspid regurgitation and none had moderate or severe regurgitation before surgery. After surgery no patient changed more than one grade of tricuspid regurgitation and none had severe regurgitation.

#### HEART RATE

Heart rate significantly increased from an average of 70 (14) beats/min before surgery to 90 (12) two days after, 93 (13) one week after, and 87 (14) six weeks after surgery. The heart rate at the six month follow up (76 (13) beats/min) did not differ significantly from the preoperative recordings. There was no correlation between changes in heart rate and the other variables measured.

#### TYPE OF SURGERY

The trends of velocity ratio and annulus motion were the same for each type of cardiac surgery performed, including accessory pathway ablation near the tricuspid or mitral annulus.

#### Discussion

Filling and emptying of the normal heart occurs almost without a change in total heart volume, due to the motion of the annuli.<sup>11-13</sup> During systole the tricuspid annulus descends towards the apex as the ventricular volume decreases. Together with atrial relaxation, this descent causes an increase in atrial volume and blood is transported from the veins into the atria. This is reflected in the systemic venous flow pattern with flow towards the atrium beginning before the onset of ventricular systole, due to atrial relaxation. The flow then increases in velocity during ventricular systole due to descent of the annulus. A second peak of inflow into the atrium is seen during ventricular diastole, when the tricuspid valve opens and the atrium acts as a passive conduit for blood from the veins into the right ventricle. In the normal venous filling pattern systolic flow is greater than diastolic flow.<sup>5,7,14</sup>

Changes in systemic venous return after cardiac surgery have been recognised by abnormalities in jugular venous pulse contours<sup>2,3</sup> and flow velocities,<sup>4,5</sup> and by changes in the flow velocities of the hepatic vein and superior vena cava.<sup>15-17</sup> Recently we showed, using intraoperative transoesophageal echocardiography, that the venous flow pattern

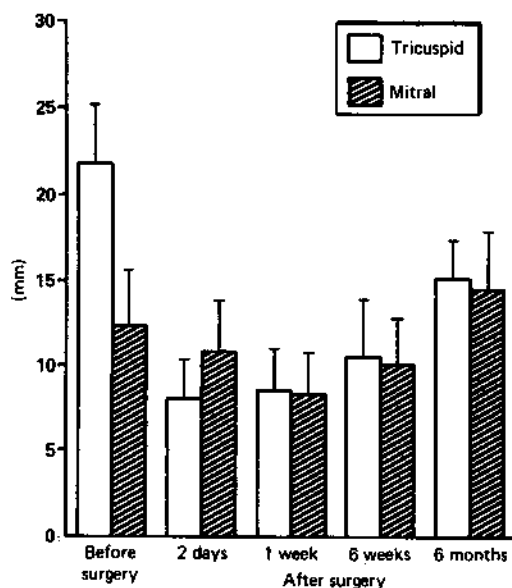
**Table 2** Tricuspid and mitral annulus motion before and at four times after cardiac surgery

	Tricuspid annulus								Mitral annulus								
	Lateral		Medial		Anterior		Posterior		Lateral		Medial		Anterior		Posterior		
	a	total	a	total	a	total	a	total	a	total	a	total	a	total	a	total	
Before	mean (SD) No	8.7 (2.2) 20	21.9 (3.4) 25	7.2 (2.5) 17	15.7 (4.0) 21	7.7 (2.2) 20	18.4 (5.3) 24	8.0 (2.7) 20	19.4 (3.9) 22	5.4 (1.7) 20	12.4 (3.2) 25	4.9 (1.4) 20	11.3 (3.1) 25	5.0 (1.5) 20	12.4 (3.5) 25	5.0 (1.8) 19	12.6 (3.2) 24
Two days	mean (SD) No	3.3 (2.3) 3	8.1 (2.3) 14	3.3 (2.2) 3	8.9 (2.2) 9	2.5 (0.9) 2	8.4 (2.5) 11	2.5 (2.1) 2	8.1 (2.3) 8	4.2 (1.3) 5	10.8 (3.0) 11	4.3 (2.2) 3	8.4 (2.2) 11	3.8 (0.5) 4	7.9 (2.4) 11	3.3 (1.5) 4	8.4 (2.3) 11
One week	mean (SD) No	3.8 (1.3) 8	8.5 (2.5) 21	3.8 (1.2) 8	7.7 (1.9) 18	3.5 (0.9) 8	7.9 (2.1) 22	3.5 (0.8) 8	8.4 (2.3) 19	3.1 (1.3) 9	8.4 (2.3) 16	3.4 (1.0) 7	6.9 (1.5) 17	3.1 (1.1) 7	7.1 (1.9) 16	3.2 (1.3) 9	7.5 (2.4) 16
Six weeks	mean (SD) No	5.2 (1.5) 6	10.5 (3.4) 19	4.3 (1.3) 4	9.1 (1.8) 14	6.0 (2.2) 3	9.1 (2.2) 16	4.6 (1.5) 5	8.8 (2.2) 18	5.2 (2.1) 9	10.1 (2.7) 17	4.0 (0.7) 5	7.7 (1.8) 16	5.0 (2.0) 5	9.5 (1.7) 17	4.5 (1.7) 2	7.8 (2.0) 15
Six months	mean (SD) No	6.1 (1.3) 9	15.1 (2.3) 9	5.8 (1.6) 9	14.3 (3.6) 9	5.0 (1.2) 8	1.3 (2.2) 8	5.8 (1.5) 9	14.1 (3.0) 9	5.6 (1.3) 7	14.6 (3.2) 7	4.3 (1.3) 7	10.4 (3.2) 7	4.9 (1.7) 7	12.0 (2.8) 7	5.1 (0.9) 7	12.3 (3.6) 7

a, atrial component of tricuspid annulus motion. See footnote to table 1 for other abbreviations.



Figure 5 Motion (mean (SD)) of the lateral aspects of tricuspid annulus and mitral annulus before and two days, one week, six weeks, and six months after cardiac surgery.



becomes abnormal immediately after termination of cardiopulmonary bypass, and is normal even with an open pericardium before cardiopulmonary bypass.<sup>6</sup> The progression of these changes and their relation to the motion of the tricuspid annulus, however, have not been studied before.

#### SYSTEMIC VENOUS FLOW PATTERN

The venous filling pattern is abnormal immediately after cardiopulmonary bypass.<sup>6</sup> A decrease in systolic flow, reversed flow at the end of ventricular systole, a predominant diastolic component, and reversal in the systolic to diastolic ratio are present at this time. The current study shows that the abnormal pattern is still present in most patients up to six months after surgery, although it is not as pronounced as in the early postoperative period.

The abnormal pattern of systemic venous flow after open heart surgery has also been noted by others.<sup>3-5</sup> Sivaciyan and Ranganathan studied jugular venous flow velocity patterns in a group of patients after cardiac surgery and noted an equalisation of systolic and diastolic flows or predominance of the diastolic component.<sup>5</sup> They concluded that these changes were due to a decrease in right atrial compliance affecting its contractility and relaxation and contributing to a decreased systolic flow. Similar findings and conclusions were also noted in a group of patients who underwent coronary artery bypass grafting.<sup>4</sup> Yoshida *et al* found decreased or reversed systolic flow in postoperative patients and concluded that hepatic venous flow was not accurate in evaluating tricuspid regurgitation after cardiac surgery.<sup>15</sup>

This pattern of decreased or inverted systolic to diastolic ratio has also been described in other clinical situations. In the presence of impaired right ventricular function with increased right ventricular end diastolic and right atrial pressures (as seen in patients with right heart failure), there is poor descent of the base of the ventricle, giving a jugular venous pulse pattern with only a "v" wave, a "y" descent, and a single diastolic component in the flow pattern.<sup>5</sup> In patients with atrial fibrillation<sup>15</sup>

or significant tricuspid regurgitation<sup>16-18</sup> there is also a diminished or even reversed systolic component. Recently it was shown that a decrease in systolic peak flow velocity and an increase in both diastolic and reversed flows occur during inspiration in patients with cardiac amyloidosis.<sup>19</sup>

#### TRICUSPID ANNULUS MOTION

Echocardiographic analysis of tricuspid annulus motion has been reported earlier by Kaul *et al* using the two dimensional technique<sup>20</sup> and recently by us using cross sectionally guided M mode.<sup>9</sup> In normal subjects echocardiography shows a distinct difference in motion between the tricuspid and mitral annulus; whereas the mitral annulus moves like a piston, the tricuspid annulus tilts or swings from a hinge point at the septal margin, with the greatest motion along the lateral aspect of the annulus. The lateral point of the tricuspid annulus has a larger excursion than the corresponding point on the mitral annulus.<sup>9</sup> A decreased mitral annulus motion is associated with left ventricular systolic dysfunction<sup>21-23</sup> and is accompanied by an altered pulmonary venous inflow pattern with diastolic instead of the normal systolic dominance.<sup>21</sup> A decrease in the motion of the tricuspid annulus is associated with right ventricular dysfunction,<sup>20</sup> but there are no reports regarding its possible association with changes in systemic venous return to the heart.

The present study shows a remarkable change in pattern and decrease in tricuspid annulus motion after surgery. Postoperatively the tricuspid annulus moved like a piston, initially with a very low amplitude. This motion pattern was still present six months after surgery, but the amplitudes of motion of the anterior, lateral, and posterior parts of the tricuspid annulus were significantly higher than at the second postoperative day. A similar evolution was seen for the tricuspid annulus "a" wave, present in most patients before operation and six months after, but present in only a few two days to six weeks after surgery. This cannot be explained by difficulty in its identification with the increase in heart rate, as the mitral annulus "a" wave was present significantly more often during this time.

The time course of change in the motion of the tricuspid annulus suggests a multifactorial effect. The pronounced decrease in amplitude found early after surgery and the later return towards normal may be a consequence of impaired right heart function secondary to inadequate preservation of the right heart during surgery. Intensive efforts have been made to preserve the heart by general hypothermia, intracoronary cold preservation solutions, and topical chilling of the heart. The success in preservation of the left heart is probably higher than for the right heart, which is exposed to room temperature and radiation heat from operating room lights. Also the right atrium is perfused with blood returning from the body at a temperature of approximately 30°C.<sup>24-27</sup> Our findings may thus reflect a right ventricular equivalent of "stunned myocardium."<sup>28</sup> The

different response in the pattern of pulmonary and systemic venous flow noted intra-operatively<sup>6</sup> and the difference in mitral and tricuspid annulus motion seen in the present study may be a reflection of the different success in myocardial preservation of the right and left heart chambers. The decrease in both total amplitude and "a" wave amplitude of tricuspid annulus motion suggests that right atrial and right ventricular function may both be impaired. Oedema and bleeding at the insertion site of the right atrial cannula may also contribute to this change. The lack of significant change in right ventricular area after surgery may reflect an altered pattern of right ventricular contraction, implying a change in ventricular geometry and so favouring a more mechanical explanation for the changes.

An alternative explanation includes a mechanical impediment to tricuspid annulus motion. In the early postoperative period this might be secondary to the presence of chest tubes, oedema, and bleeding and in the later postoperative period it could be due to adhesions between the heart and surrounding tissues. This hypothesis is supported by the observed lack of total recovery of the lateral aspect of the tricuspid annulus. The findings soon after surgery are likely to be due to a transient change in right heart function combined with mechanical impediment whereas the later findings may be mainly due to mechanical impediment.

This study confirms the previously observed postoperative changes in the pattern of flow in the hepatic vein and superior vena cava from a normal pattern with systolic dominance to an abnormal pattern with diastolic dominance. In most patients after surgery forward systolic flow was minimal and frank systolic flow reversal, corresponding to the right atrial pressure "v" wave, was often present. This could not be explained by tricuspid regurgitation, which was an infrequent finding in our patient group. There was a significant relation between the amplitude of tricuspid annulus motion and venous flow pattern, suggesting that the change in venous pattern may be secondary to the decrease in tricuspid annulus motion, which is in turn a marker of right ventricular function. The presence of cannulas inside the right atrium during cardiopulmonary bypass might produce atrial trauma, oedema, and increased right atrial stiffness, which, in combination with poor preservation of the right atrium, will probably affect both atrial contractility and relaxation, thereby decreasing systolic forward flow.

#### LIMITATIONS OF THE STUDY

Patients received several types of clinically indicated drugs. For ethical reasons it was not possible to have all patients under the same drug regimen. Loading conditions of the left and right heart also influence Doppler flow velocities but could not be rigidly controlled.<sup>29-31</sup> Postoperative intracardiac pressures were not measured. The changes in the Doppler velocity patterns and annulus motion were quite consistent, however, despite these limitations.

The contraction of the heart involves not only annular descent and myocardial thickening but also a twisting motion of the ventricles.<sup>32</sup> This motion was not analysed in our present study so changes in torsion induced by surgery that might affect right heart filling would go undetected by these methods.

#### CLINICAL IMPLICATIONS

The present study improved the understanding of the sequence and possible pathophysiology of previously described changes in systemic venous return after cardiac surgery. It shows that these changes are not related to the type of surgery, total time of cardiopulmonary bypass or aortic cross clamp time, use of cardioplegia, type of myocardial preservation, or presence of tricuspid regurgitation. These findings have significant implications for evaluating influences of various perioperative interventions on maintaining cardiac dynamics. They also reinforce the previously recognised caution regarding interpretation of systemic venous patterns in patients even with remote cardiac surgery.

We thank Joan Rosel and Gretchen Scott for help in preparing the typescript.

BW was supported by grants from the Swedish Medical Research Council (9224), Swedish Medical Association, Swedish Heart Lung Foundation, the Fulbright Commission, and Ollie and Elof Ericsson's Foundation; FJP was supported by a Research Fellowship of the Fundação Calouste Gulbenkian (Lisbon, Portugal). The present address for BW is: Department of Clinical Physiology, University Hospital, Linköping, Sweden.

- 1 Harman H. The jugular venous tracing. *Am Heart J* 1960;59:698-717.
- 2 Matsuhisa M, Yui Y, Kondo C, Niki Y, Niki T, Mori H, et al. Postoperative changes of jugular pulse tracing. *J Cardiol* 1976;6:403-12.
- 3 Wann LS, Morris SN, Tavel ME. Effects of cardiopulmonary bypass on the jugular venous pulse. *Am Heart J* 1977;94:262-4.
- 4 Ranganathan N, Sivaciyan V, Pryszyk M, Freeman MR. Changes in jugular venous flow velocity after coronary artery bypass grafting. *Am J Cardiol* 1989;63:725-9.
- 5 Sivaciyan V, Ranganathan N. Transcutaneous jugular venous flow velocity recording: clinical and hemodynamic correlates. *Circulation* 1987;57:930-9.
- 6 Pinto FJ, Wranne B, St. Goar FG, Siegel LC, Haddow G, Schnitzler I, et al. Systemic venous flow changes during open-heart surgery: timing and mechanisms [abstract]. *Circulation* 1990;82 (suppl III):723.
- 7 Appleton CP, Hatle LK, Popp RL. Superior vena cava and hepatic vein echocardiography in healthy adults. *J Am Coll Cardiol* 1987;10:1032-9.
- 8 Czer LSC, Maurer G, Bolger A, DeRobertis M, Kleinman J, Gray RJ, et al. Tricuspid valve repair: operative and follow-up evaluation by Doppler colour flow mapping. *J Thorac Cardiovasc Surg* 1989;98:101-11.
- 9 Hammarstöm E, Wranne B, Pinto FJ, Puryear J, Popp RL. Tricuspid annulus motion. *J Am Soc Echocardiogr* 1991;4:131-9.
- 10 Bazett HC. Analysis of the time relations of the electrocardiogram. *Heart* 1920;7:353-70.
- 11 Hamilton WF, Rompf JH. Movements of the base of the ventricle and the relative constancy of the cardiac volume. *Am J Physiol* 1932;102:559-65.
- 12 Hoffman EA, Rittman EL. Invariant total heart volume in the intact thorax. *Am J Physiol (Heart Circ Physiol)* 1985; 249:H883-90.
- 13 Hoffman EA, Rittman EL. Heart-lung interaction; effect on regional lung air content and total heart volume. *Ann Biomed Eng* 1987;15:241-57.
- 14 Cohen ML, Cohen BS, Kronzon I, Lighty GW, Winer HE. Superior vena caval blood flow velocities in adults: a Doppler echocardiographic study. *J Appl Physiol* 1986; 61:215-9.
- 15 Yoshida K, Yoshikawa J, Kato H, Yanagihara K, Okumachi F, Koizumi K, et al. Tricuspid regurgitation evaluated by Doppler hepatic vein flow patterns. *J Cardiol* 1985; 15:1157-69.
- 16 Sakai K, Nakamura K, Satomi G, Kondo M, Hirose K. Evaluation of tricuspid regurgitation by blood flow pattern in the hepatic vein using pulsed Doppler technique. *Am Heart J* 1984;108:516-23.

- 17 Sakai K, Nakamura K, Satomi G, Kondo M, Hirotsawa K. Hepatic vein blood flow pattern measured by Doppler echocardiography as an evaluation of tricuspid valve insufficiency. *J Cardiogr* 1983;13:33-43.
- 18 Pennestri F, Loperfido F, Salvatori MP, Mongiardo R, Ferrazza A, Guccione P, et al. Assessment of tricuspid regurgitation by pulsed ultrasonography of the hepatic veins. *Am J Cardiol* 1984;54:363-8.
- 19 Klein AL, Hatle LK, Burstow DJ, Taliencio CP, Seward JB, Kyle RA, et al. Comprehensive Doppler assessment of right ventricular diastolic function in cardiac amyloidosis. *J Am Coll Cardiol* 1990;15:99-108.
- 20 Kaul S, Tei C, Hopkins JM, Shah PM. Assessment of right ventricular function using two-dimensional echocardiography. *Am Heart J* 1984;107:526-31.
- 21 Keren G, Sonnenblick EH, LeJemtel TH. Mitral annulus motion: relation to pulmonary venous and transmitral flow in normal subjects and in patients with dilated cardiomyopathy. *Circulation* 1988;8:621-9.
- 22 Höglund C, Alam M, Thorstrand C. Effects of acute myocardial infarction on the displacement of the atrioventricular plane: an echocardiographic study. *J Intern Med* 1989;226:251-6.
- 23 Simonson JS, Schiller NB. Descent of the base of the left ventricle: an echocardiographic index of left ventricular function. *J Am Soc Echocardiogr* 1989;2:25-35.
- 24 Fisk RL, Ghaswala D, Guilbeau EJ. Asymmetrical myocardial hypothermic cardioplegia. *Ann Thorac Surg* 1982;34:318-23.
- 25 Gonzalez AC, Brandon TA, Fortune RL, Casano SF, Martin M, Benneson DL, et al. Acute right ventricular failure is caused by inadequate right ventricular hypothermia. *J Thorac Cardiovasc Surg* 1985;89:386-99.
- 26 Christakis GT, Frenes SE, Weisel RD, Ivanov J, Madonik MM, Seawright SJ, et al. Right ventricular dysfunction following cold potassium cardioplegia. *J Thorac Cardiovasc Surg* 1985;90:243-50.
- 27 Velardi AR, Wildmer SJ, Cilley JH Jr, Spence RK, Witkowski TA, DelRossi AJ. Right ventricular myocardial protection through intracavitary cooling in cardiac operations. *J Thorac Cardiovasc Surg* 1989;98:1077-82.
- 28 Braunwald E, Kloner RA. The stunned myocardium: prolonged postischemic ventricular dysfunction. *Circulation* 1982;66:1146-9.
- 29 Choong CY, Abascal VM, Thomas JD, Guerrero JL, McGlew S, Weyman AE. Combined influence of ventricular loading and relaxation on the transmitral flow velocity profile in dogs measured by Doppler echocardiography. *Circulation* 1988;78:672-83.
- 30 Ishida Y, Meisner JS, Tsujioka K, Gallo JI, Yoran C, Frater RWM, et al. Left ventricular filling dynamics: influence of left ventricular relaxation and left atrium pressure. *Circulation* 1986;74:187-96.
- 31 Nishimura RA, Abel MD, Hatle LK, Tajik AJ. Relation of pulmonary vein to mitral flow velocities by transesophageal Doppler echocardiography. Effect of different loading conditions. *Circulation* 1990;81:1488-97.
- 32 Rushmer RF. Changes in configuration of the ventricular chambers during the cardiac cycle. *Circulation* 1951;4:211-8.



**Heart**

## **Abnormal right heart filling after cardiac surgery: time course and mechanisms.**

B Wranne, F J Pinto, E Hammarström, F G St Goar, J Puryear and R L Popp

*Br Heart J* 1991 66: 435-442  
doi: 10.1136/hrt.66.6.435

---

Updated information and services can be found at:  
<http://heart.bmj.com/content/66/6/435>

---

### **Email alerting service**

*These include:*

Receive free email alerts when new articles cite this article. Sign up in the box at the top right corner of the online article.

---

### **Notes**

---

To request permissions go to:  
<http://group.bmj.com/group/rights-licensing/permissions>

To order reprints go to:  
<http://journals.bmj.com/cgi/reprintform>

To subscribe to BMJ go to:  
<http://group.bmj.com/subscribe/>