

# Nitroglycerin-Induced Coronary Vasodilation in Cardiac Transplant Recipients

## Evaluation With In Vivo Intracoronary Ultrasound

Fausto J. Pinto, MD; Frederick G. St. Goar, MD; Tim A. Fischell, MD;  
Michael L. Stadius, MD; Hannah A. Valantine, MD;  
Edwin L. Alderman, MD; and Richard L. Popp, MD

**Background.** Coronary artery vasomotion is altered after cardiac transplantation. The impact of accelerated transplant coronary atherosclerosis and myocardial rejection on vasomotion is not well understood. Intravascular ultrasound is a new imaging method with the ability to study real-time changes in coronary artery dimensions.

**Methods and Results.** Epicardial coronary artery response to nitroglycerin was studied in 32 cardiac transplant recipients (age,  $47 \pm 11$  years) 3 weeks to 10 years after transplantation with intracoronary ultrasound. Cross-sectional luminal area and diameter were measured at a fixed position in the left anterior descending artery immediately before and every 30 seconds for 5 minutes after 0.4 mg of sublingual nitroglycerin. Cross-sectional area increased from a baseline of  $13.1 \pm 3.9$  mm<sup>2</sup> to  $15.8 \pm 3.9$  mm<sup>2</sup> at maximal vasodilation; luminal diameter increased from  $4.0 \pm 0.6$  mm to  $4.5 \pm 0.6$  mm. This increase reached statistical significance ( $p < 0.001$ ) at 1.5 minutes after administration of nitroglycerin; mean maximum increase occurred at 4.5 minutes (24% for cross-sectional area and 11% for luminal diameter). Patients with biopsy-proven mild or moderate concurrent rejection had a significantly blunted vasodilatory response versus the nonrejection group (9% versus 27% for cross-sectional area,  $p < 0.04$ ), although a vasodilatory effect was still present. Nitroglycerin response was well preserved in patients up to 10 years after transplantation; however, there was a trend toward a decreased response in patients studied immediately after transplantation (21% versus 29%,  $p = 0.37$ ). Coronary intimal thickness, as measured by ultrasound, had no impact on the vasodilatory response ( $R = 0.23$ ,  $p = 0.34$ ).

**Conclusions.** Vasodilatory response to nitroglycerin in cardiac transplant recipients is attenuated during episodes of cardiac rejection. This response is preserved in long-term survivors and is independent of the degree of intimal thickening. Intravascular ultrasound provides a new method to document real-time epicardial coronary vasomotion. (*Circulation* 1992;85:69-77)

The rapid development of diffuse occlusive coronary artery disease in cardiac allografts has emerged as a major predictor of allograft loss in patients surviving 1 year beyond transplantation.<sup>1-4</sup> Both immunological and nonimmunological factors have been implicated in the development of graft coronary artery disease<sup>2,3</sup>; however, no conclusive correlation with specific factors has been estab-

lished. The functional response to the endothelium-dependent vasodilator acetylcholine is abnormal in cardiac transplant recipients.<sup>5-7</sup> These abnormalities are identical to those observed in nontransplant patients with coronary atherosclerosis<sup>8,9</sup> and in patients with angiographically normal coronary arteries but with risk factors for coronary atherosclerosis.<sup>10</sup>

Vasodilatory response to nitroglycerin is preserved in nontransplant patients with coronary artery disease.<sup>11,12</sup> The magnitude of dilation differs according to vessel size, with the smallest vessels showing the greater magnitude of vasodilation.<sup>11,12</sup> In addition, segments narrowed by the atherosclerotic process commonly dilate after nitroglycerin.<sup>11</sup> Cardiac rejection produces changes in vascular function leading to a decrease in myocardial perfusion.<sup>13-18</sup> However,

From Stanford University School of Medicine, Division of Cardiovascular Medicine, Stanford, Calif.

Supported in part by a Fellowship Award from Fundação Calouste Gulbenkian (F.J.P.), Lisbon, Portugal.

Address for reprints: Richard L. Popp, MD, Division of Cardiovascular Medicine, Stanford University School of Medicine, Stanford, CA 94305.

Received April 18, 1991; revision accepted September 3, 1991.

the response of transplant coronary arteries to nitroglycerin early versus late after transplantation and during rejection and the influence of local presence of atheroma have not been evaluated. Intravascular ultrasound is a new imaging technique with the ability to define, and thus measure, luminal areas and arterial wall components<sup>19-22</sup> and serves as a potential tool to assess dynamic vasomotor responses in epicardial coronary arteries.

The purpose of the present investigation was three-fold: Assess the time course of the coronary vasodilatory response to nitroglycerin by using intracoronary ultrasound, study the impact of acute myocardial rejection on the vasodilatory response to nitroglycerin, and quantitate the amplitude of the vasodilatory response in relation to the extent of intimal thickening measured by intracoronary ultrasound.

### Methods

#### Patient Population

Thirty-two cardiac transplant recipients, 24 men and eight women undergoing annual routine coronary arteriograms (mean age,  $46.5 \pm 10.9$  years; range, 20-62 years), were studied. Time after transplantation ranged from 2 weeks to 10 years, with a mean of

2.5 years. Eleven patients were studied within 1 month of transplantation during a routine baseline angiogram performed immediately before posttransplantation hospital discharge. All patients were managed with standard immunosuppressive regimens including prednisone, azathioprine, and cyclosporine. The cyclosporine serum levels were adjusted to 50-150 ng/dl by radioimmunoassay technique at approximately 2-3 months after the transplant procedure. Antirejection therapy, when indicated, consisted of increased corticosteroid dose and, in refractory cases, administration of rabbit antithymocyte globulin. Fourteen patients were on calcium channel blockers, which were stopped 48 hours before the catheterization protocol. Endomyocardial biopsies were performed at the time of the coronary arteriographic procedure to assess rejection and were graded according to the Billingham criteria.<sup>23</sup> All subjects gave informed written consent to the protocol approved by the committee for the protection of human subjects in research at the Stanford University Medical Center.

#### Procedure

The intracoronary imaging system consists of a high-frequency 30-MHz transducer and rotating mir-

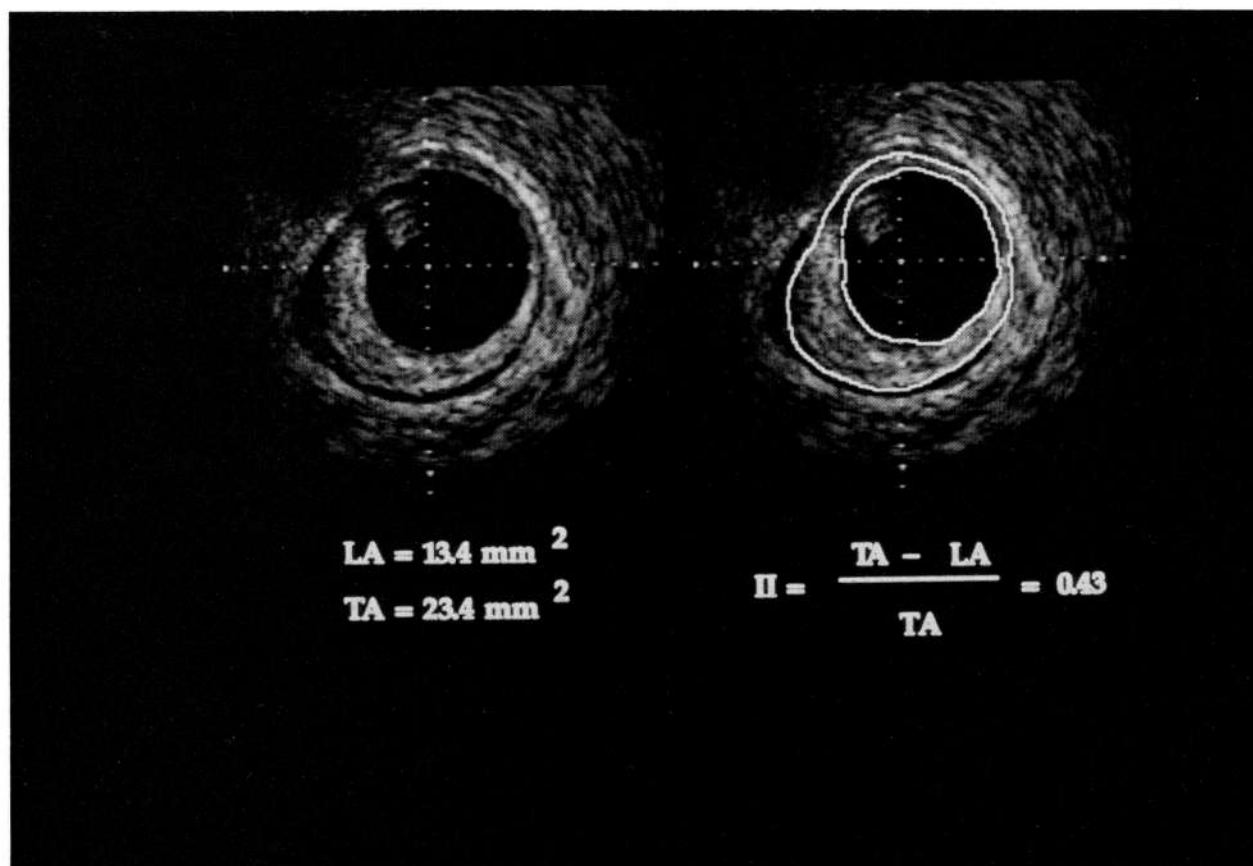


FIGURE 1. Intracoronary ultrasound image obtained in a patient 7 years after transplantation, showing three-layer appearance of vessel wall. Right panel shows the method of determining the index of intimal thickening (II). LA, luminal area; TA, total area. Perpendicular grid of tick marks are at 0.5-mm intervals. Bright shadow at 11 o'clock position at the edge of the catheter is an artifact caused by mechanical strut and coronary guide wire.

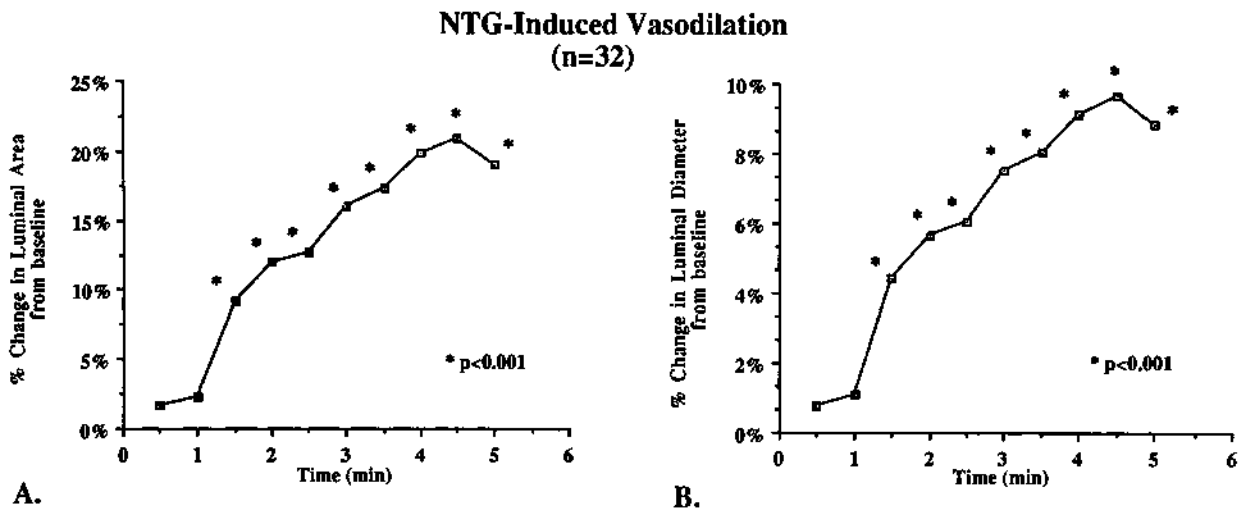


FIGURE 2. Plots of mean data from this study showing nitroglycerin-induced changes in diastolic cross-sectional area (panel A) and diameter (panel B) vs. time after administration of 0.4 mg sublingual nitroglycerin. Values were statistically different from baseline at 1.5 minutes after nitroglycerin administration.

ror enclosed within an acoustic housing at the tip of a 5F, flexible, 135-cm-long, rapid exchange catheter (CVIS Inc., Sunnyvale, Calif.). The catheter assembly houses a flexible drive cable connected to a motor at the distal end, which is used to rotate the mirror at 1,800 rpm. The ultrasound beam, reflected onto the rotating mirror, creates a 360° real-time image perpendicular to the catheter. At focal depth, the axial resolution of the system is 150  $\mu\text{m}$  and lateral resolution is 200  $\mu\text{m}$ . The radius of penetration is approximately 5 mm. The imaging catheter has a lumen that accommodates a 0.014-in. coronary guide wire that exits the catheter centrally, distal to the transducer, via a flexible, tapered tip. After full anticoagulation with 10,000 units of intravenous heparin, the catheter was introduced through a high-flow 8F guiding catheter (internal diameter, 0.082 in.) over a coronary guide wire into the left anterior descending or left circumflex artery. This allows for manipulation of the ultrasound catheter in a coronary artery in a fashion similar to coronary balloon angioplasty systems. Several segments in each patient (up to four) were visualized simultaneously with ultrasound and cine angiography in right anterior oblique caudal projection. When the ultrasound catheter was in a midcoronary segment void of branch vessels, 0.4 mg of sublingual nitroglycerin was given to the patient. Ultrasound settings, including receiver gain compensation, compression, and rejection were adjusted at the time of image acquisition to generate images with the largest gray-scale range to optimize visualization of the vessel-lumen interface. Once these settings were optimized, the imaging catheter was kept in the same position for 5 minutes to visualize and serially measure the induced changes. During this period of time, the gain settings were not changed. All vessel images were within the focal zone of the transducer between 1.5 and 4.5 mm. Each segment served as its

own control. Heart rate was determined from the electrocardiographic recordings and blood pressure was monitored during the procedure.

#### Intravascular Ultrasound Measurements

All recordings were made on 0.5-in. videotape for subsequent measurement from single-frame images. Representative sequential frames were digitized on a 512 $\times$ 512 $\times$ 8-bit matrix in 34-frame sequences by an image processing computer dedicated to echocardiographic analysis (Dextra Medical Inc.). All patients had heart rates above 60 beats per minute (mean, 85 $\pm$ 13 beats per minute), permitting at least one full cardiac cycle to be digitized for each analysis sequence. Resident software algorithms for smoothing and contrast enhancement were used to optimize visualization of vascular wall layers. The ultrasound measurements included vessel cross-sectional areas measured by tracing the inner boundary of the coronary artery lumen-wall interface from a single frame and mean vessel diameter calculated from the area. In addition, the combined area of lumen plus intima was measured. Intimal thickness was measured from the processed images as the distance from the leading edge of the luminal echodense band to the leading edge of the medial band. An index of intimal thickness was calculated as ([luminal+intimal area]–[luminal area])/([luminal+intimal area]) (Figure 1). Intimal thickness index, luminal, and intimal areas were measured every 30 seconds for 5 minutes after administration of nitroglycerin. Each arterial segment at the baseline (i.e., before nitroglycerin) was used as the standard for comparison of subsequent change. Intimal thickening was defined as ultrasound evidence of three vessel wall layers appearing over greater than 75% of the lumen circumference. This definition was based on recent *in vitro* and *in vivo* imaging studies that demonstrated that young nondiseased coronary vessels show a uniform

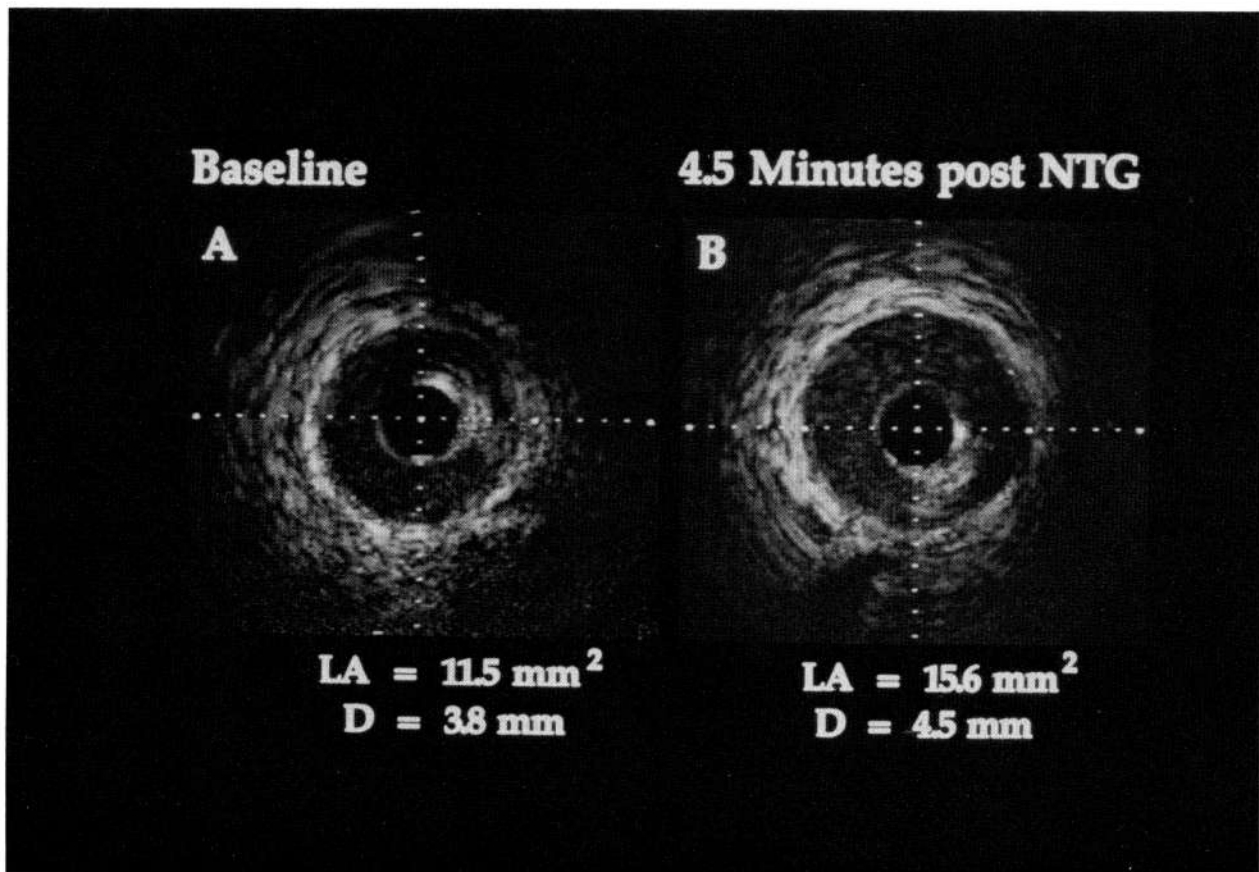


FIGURE 3. Images of coronary artery cross section before and after nitroglycerin. Left panel shows cross section of the left anterior descending artery at baseline before nitroglycerin in a patient studied 1 year after transplantation. Right panel shows the same cross section visualized 4.5 minutes after administration of 0.4 mg sublingual nitroglycerin (NTG). D, diameter; LA, luminal area. Perpendicular grid of tick marks is at 0.5-mm intervals.

vessel wall appearance with lack of the characteristic three layers.<sup>24</sup> Two ultrasound sites from 10 patients ( $n=20$ ) were randomly selected and measured by one observer at two separate times and once by a second observer for intraobserver and interobserver variability. These were expressed as a linear regression between the two observations and as a percent error derived as the absolute difference between observations.<sup>25</sup> These results were recently reported.<sup>20</sup> An excellent reproducibility was demonstrated, with an interobserver variability for the mean diameter of 3.3% with a correlation coefficient of 0.97 and intraobserver variability of 2.7% with a correlation coefficient of 0.98.<sup>20</sup>

#### Clinical Characteristics

Analyzed clinical characteristics included duration of ischemia during transplantation, time from transplantation, and rejection status at the time of the study. These were correlated with the amount of nitroglycerin-induced changes.

#### Data Analysis

Values are expressed as mean  $\pm$  1 SD. Differences in mean values between groups were compared using a two-tailed unpaired Student's *t* test. Nitroglycerin

responses at different times after administration were analyzed by two-way analysis of variance (ANOVA). For significant *F* ratios, group mean values were compared using Fisher's test. A probability value of less than 0.05 was considered to be statistically significant.

## Results

#### Systemic Hemodynamics

Mean heart rate and systolic blood pressure were  $85 \pm 13$  beats per minute and  $137 \pm 36$  mm Hg before and  $89 \pm 13$  beats per minute and  $122 \pm 23$  mm Hg after administration of nitroglycerin.

#### Vascular Response to Nitroglycerin

End-diastolic cross-sectional area for the whole group increased from a baseline of  $13.1 \pm 3.9$  mm<sup>2</sup> to a maximum value of  $15.8 \pm 3.9$  mm<sup>2</sup> ( $24 \pm 19\%$  change). The derived mean diameter increased from  $4.0 \pm 0.6$  mm to  $4.5 \pm 0.6$  mm ( $11 \pm 8\%$  change). The increase in luminal area and diameter versus baseline reached statistical significance ( $p < 0.001$ ) at 1.5 minutes and peaked at 4.5 minutes (Figures 2 and 3). No

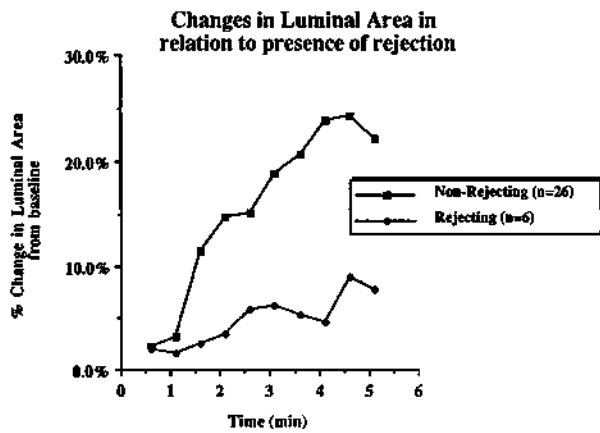


FIGURE 4. Plot of mean values for maximal percent change in luminal area vs. time after administration of nitroglycerin in six patients with biopsy-proven rejection (solid symbols) and those 26 patients without signs of rejection on biopsy (open symbols). The difference in the magnitude of the response was statistically significant ( $p < 0.03$ ) at 4 minutes.

patient showed evidence of coronary spasm before nitroglycerin was given. (Also see Table 1).

Six patients had endomyocardial, biopsy-proven rejection (mild to moderate) at the time of the studies (four patients were studied within 3 weeks of transplantation and the other two patients more than 1 year after transplantation). In this group of patients, the ability to vasodilate was still present though significantly blunted when compared with patients without rejection (9% versus 27% for cross-sectional area,  $p < 0.04$ ; 4% versus 12% for diameter,  $p < 0.03$ ) (Figure 4).

The vasodilatory response to nitroglycerin was well preserved among the remaining 26 patients without biopsy-proven rejection for up to 10 years after transplantation. However, the seven patients studied in the nonrejecting group less than 1 month after transplantation showed a consistent trend toward a decreased vasodilatory response when compared with those patients more than 1 year after transplantation, although the difference did not reach statistical significance (21% versus 29% for cross-sectional area,  $p = 0.37$ ; 10% versus 13% for diameter,  $p = 0.36$ ) (Figure 5). When compared with the four patients with early rejection, this group of seven patients without rejection showed a trend toward increased vasodilatory response, although this did not reach statistical significance (21% versus 8% for cross-sectional area,  $p = 0.20$ ; 10% versus 4% for diameter,  $p = 0.18$ ). In the 19 patients studied more than 1 year after transplantation, there was no significant correlation between the degree of vasodilation and time since transplantation ( $R = 0.35$ ;  $p = 0.14$ ) (Figure 6A).

Twenty-three patients (72%) showed intimal thickening measurable by intravascular ultrasound (mean,  $0.28 \pm 0.17$  mm) and an intimal thickening ratio of  $0.23 \pm 0.12$ . Twenty of these 23 patients (87%) had no angiographic evidence of coronary artery disease. Neither the amount of intimal thickening, as mea-

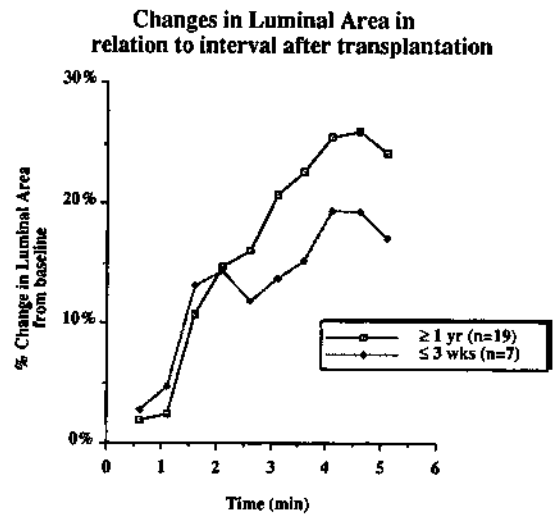


FIGURE 5. Plot of mean values for maximal percent change in luminal area vs. time after nitroglycerin administration in two groups. Patients studied within 3 weeks of transplantation and those studied more than 1 year after transplantation are noted by symbols. Decreased vasodilatory response is implied but the difference did not reach statistical significance.

sured with intravascular ultrasound, nor the presence of angiographic disease altered the vasodilatory response to nitroglycerin ( $R = 0.23$ ,  $p = 0.34$ ) (Figure 6B). Nitroglycerin response also was independent of the baseline diameter ( $R = 0.32$ ,  $p = 0.09$ ). This suggests that the response to nitroglycerin was not primarily influenced by basal tone.

## Discussion

Changes in coronary artery response to pharmacological interventions have been studied with various technologies, including quantitative angiography,<sup>26,27</sup> intracoronary Doppler catheterization,<sup>28,29</sup> transthoracic high-frequency (7.5 MHz) echocardiography,<sup>30</sup> and transesophageal echocardiography.<sup>31,32</sup> Each technique has limitations, including inaccuracy in detecting changes in vessel size, limited length of segments visualized, and need for contrast agents. Intravascular ultrasound is a recently developed imaging modality<sup>33-35</sup> with the ability to define and measure the structural components of the arterial wall.<sup>21,22,36</sup> Prior studies have shown its reproducibility and variability in measuring wall thickness and luminal diameters.<sup>19,20</sup> Our group has recently demonstrated a good correlation of intravascular ultrasound and quantitative angiography, although intracoronary ultrasound measurements were consistently larger than angiographic values.<sup>20</sup> This may be partially related to catheter angulation inside the lumen, among other factors.<sup>20</sup> The present study shows that intravascular ultrasound can be used to accurately measure the time course and magnitude of coronary artery luminal changes in response to nitroglycerin. These findings demonstrate the potential of intravascular ultrasound as a tool to study epicardial coro-

TABLE 1. Coronary Lumen Response to Nitroglycerin in 32 Cardiac Transplant Recipients

Patient	Patient age (years)	Donor age (years)	Patient sex	Time from Tx (months)	Biopsy	Index int th	Int th (mm)	% Change (luminal area)
1	24	20	F	69	-	0.12	0.13	31
2	20	23	F	48	-	0.08	0.10	10
3	47	29	M	36	+	0.35	0.57	26
4	56	19	F	<1	+	nm	nm	13
5	32	16	M	12	-	0.16	0.16	47
6	49	23	F	<1	-	nm	nm	16
7	46	27	M	27	-	0.37	0.44	47
8	32	20	M	72	-	0.36	0.37	82
9	51	14	M	108	-	0.35	0.45	55
10	31	23	F	27	-	0.30	0.33	36
11	46	21	M	118	-	0.50	0.69	19
12	51	28	M	48	-	0.21	0.25	32
13	59	31	M	48	-	0.16	0.17	19
14	59	23	M	48	-	0.31	0.45	13
15	47	21	M	12	-	0.26	0.30	25
16	41	43	M	<1	+	0.17	0.20	16
17	44	29	M	17	+	0.38	0.45	-5
18	53	22	M	54	-	0.32	0.39	24
19	59	33	M	<1	-	nm	nm	9
20	56	37	M	<1	-	0.13	0.11	61
21	47	25	M	<1	-	0.10	0.13	15
22	62	16	F	51	-	0.14	0.15	36
23	53	19	M	15	-	0.14	0.18	9
24	54	33	M	12	-	nm	nm	4
25	35	17	M	<1	-	nm	nm	22
26	51	38	M	<1	+	0.11	0.12	2
27	45	17	M	60	-	0.10	0.10	41
28	60	21	M	<1	-	nm	nm	14
29	50	41	F	46	-	0.18	0.24	23
30	52	15	F	<1	-	nm	nm	13
31	47	34	M	<1	+	nm	nm	2
32	29	21	M	12	-	nm	nm	3

Tx, transplant; int th, intimal thickness; F, female; M, male; -, no rejection; +, rejection; nm, nonmeasurable.

nary artery vasomotor responses induced by pharmacological interventions.

#### Coronary Vasomotion in Cardiac Transplants

In normal native coronary arteries, vasodilatory response to a number of agents is mediated via the release of endothelium-derived relaxing factor (EDRF).<sup>37,38</sup> Studies from several groups have shown an abnormal paradoxical vasoconstrictor response to the endothelium-dependent vasodilator acetylcholine in the presence of coronary atherosclerosis.<sup>8,9</sup> More recently, this same observation of abnormal acetylcholine responses has been reported in patients with angiographically normal coronary arteries but with risk factors for coronary artery disease.<sup>10</sup> This may reflect early atherosclerosis at a stage not detectable by angiography or an isolated disturbance of endothelial function that precedes the development of atherosclerosis.<sup>10</sup> The same vasoconstrictor response

to acetylcholine has been documented in some transplant recipients, showing that by 1–2 years after transplantation, endothelium-dependent relaxation is abnormal in the majority of coronary arteries even in the absence of angiographic disease.<sup>5–7</sup> These endothelial defects are probably due to the development of early atherosclerosis not detected by angiography.<sup>5</sup>

Recently, Dumont et al,<sup>18</sup> using canine heart transplants, have shown that nitroglycerin elicits its coronary vasodilator effect even in the setting of acute myocardial rejection. Other studies have shown a reduction in myocardial perfusion associated with rejection.<sup>13,14</sup> Multiple explanations have been given, including arteriolar damage and capillary destruction, vascular spasm, or release of vasoactive substances elicited by immunological reactivity.<sup>15</sup> Perivessel edema, diffuse hemorrhages, vessel wall thickening, and lymphocytic infiltration seen on myocardial biopsy reduce lumen diameters and compro-

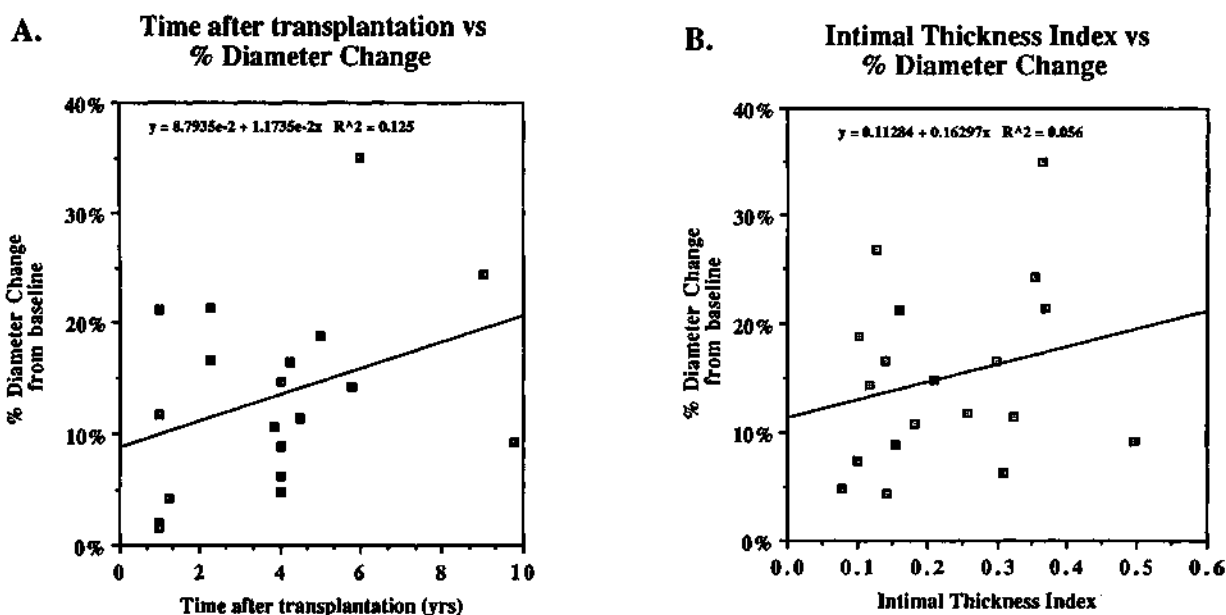


FIGURE 6. Panel A: Scatterplot of induced percent changes in luminal diameter and area vs. time after cardiac transplantation. No significant correlation is observed. Panel B: Scatterplot of maximal percent diameter change after nitroglycerin vs. intimal thickness index measured from intracoronary images. No significant correlation is observed.

mise myocardial perfusion. This contributes to the hypoxia observed with advanced states of rejection.<sup>16,17,39</sup> The correlation observed between the number and severity of rejection episodes and the development of accelerated coronary artery disease may be influenced by these vascular abnormalities.<sup>40</sup>

In the present study, transplant coronary arteries showed a preserved vasodilatory response to nitroglycerin several years after transplantation. However, this vasodilatory response was significantly blunted in patients with biopsy-proven rejection at the time they were studied, and a trend toward a decreased vasodilatory response was observed in those patients studied shortly after transplantation. These attenuated responses might be due to reduced basal tone or a defect in responsiveness to nitroglycerin. The fact that nitroglycerin response was independent of the baseline diameter suggests that it was not primarily due to alterations in basal tone. Therefore, a decreased sensitivity to nitroglycerin seems to be a more attractive explanation. The acute insult of transplantation, including surgical trauma and ischemia caused by graft procurement or myocardial rejection, may be responsible for the observed abnormalities in the endothelium-independent vasodilatory response to nitroglycerin. This may also explain the abnormal response to acetylcholine observed in some transplant patients shortly after transplantation and its subsequent recovery.<sup>41</sup> Our findings, although limited to a single observation for each patient, suggest that an abnormally functioning media is present during rejection and possibly shortly after transplantation. Thus, interpretation of EDRF-mediated responses at the time of myocardial rejection

and shortly after transplantation may be affected by these changes.

Nitroglycerin is a potent vasodilator that has been shown to increase the cross-sectional area of normal coronary arteries by approximately 20%.<sup>11</sup> When administered sublingually, a dose of 0.4 mg typically elicits a maximal vasodilatory response.<sup>11</sup> A differential response to nitroglycerin has been observed, with smaller vessels showing a relatively greater vasodilation.<sup>11</sup> In addition, segments narrowed by atherosclerotic processes commonly dilate after nitroglycerin<sup>12</sup> although demonstrating lower magnitude of dilation than that observed in nonstenosed arterial segments.<sup>12</sup> In our study, the magnitude of vasodilation (24% for cross-sectional area) was similar to that previously reported using quantitative angiography.<sup>11</sup> The lack of correlation between the magnitude of vasodilation and the baseline diameter may be explained by the fact that only the proximal and midsegments of the epicardial coronary arteries were visualized. Thus, vessel dimensions are more homogeneous and bigger than those reported on other studies using angiography, presenting a mean diameter of  $4.0 \pm 0.6$  mm and a mean cross-sectional area of  $13.1 \pm 3.9$  mm<sup>2</sup>. Brown et al<sup>42</sup> have shown that atherosclerotically diseased vessels have a dilatory response comparable with nondiseased vessels, although in their study, 25% of the lesions showed no significant reduction in flow resistance after nitroglycerin.

The impact of intimal thickening on vasodilatory capacity of transplanted coronary arteries is not well understood. Histopathological studies have demonstrated that many short-term and virtually all long-term survivors have significant coronary disease.<sup>1,43-46</sup> Transplant coronary artery disease of long-term allografts is

often diffuse, especially affecting the distal vessels, which may partly explain the failure of arteriography to measure accurately the severity of graft coronary artery disease.<sup>43-46</sup> In this study, we demonstrate that the degree of intimal thickness, detected by intravascular ultrasound, does not affect the response to nitroglycerin. This confirms previous reports showing vasodilation with nitroglycerin even in angiographically evident atherosclerotic coronary arteries.<sup>5,7,42</sup> One limitation of the present study is that size of the visualized segments is limited by the catheter size (5F). Thus, only proximal and midepicardial segments were studied. This limitation is more significant for patients with native coronary artery disease than transplant recipients because of the diffuse pattern of coronary artery disease observed in these patients. The use of intracoronary ultrasound to measure intimal thickness also has to be interpreted cautiously because adequate ultrasound resolution of vessel wall characteristics depends on several factors, including imaging frequency, system dynamic range, signal processing, and catheter design. The system used in this study uses a 30-MHz transducer. It has recently been shown that the intimal thickness of a coronary artery needs to be at least 150  $\mu\text{m}$  to be resolved by this system.<sup>24</sup> Although this criteria was convenient to define intimal thickening in this study, a better definition of minimal disease is needed.

### Clinical Implications

The present study shows that in vivo changes in coronary artery dimensions can be monitored with intravascular ultrasound. In cardiac transplant recipients, the vasodilatory response to nitroglycerin is independent of intimal thickening, angiographic evidence of coronary artery disease and time after transplantation. This capacity to vasodilate indicates preservation of medial smooth muscle function. However, it also shows that vasodilatory response to nitroglycerin is significantly blunted during rejection and perhaps shortly after transplantation. These findings may have implications in the medical management of cardiac transplant recipients, particularly during rejection, when vasodilator responsiveness may be extremely important for myocardial function and viability.

### References

- Gao SZ, Alderman EL, Schroeder JS, Silverman JF, Hunt SA: Accelerated coronary vascular disease in the heart transplant patient: Coronary arteriographic findings. *J Am Coll Cardiol* 1988;12:334-340
- Gao SZ, Schroeder JS, Alderman EL, Hunt SA, Silverman JF, Wiederhold V, Stinson EB: Clinical and laboratory correlates of accelerated coronary artery disease in the cardiac transplant patient. *Circulation* 1987;76(suppl V):V-56-V-61
- Bieber CP, Hunt SA, Schwinn DA, Jamieson SW, Reitz BA, Oyer PE, Shumway NE, Stinson EB: Complications in long-term survivors of cardiac transplantation. *Transplant Proc* 1981;8:207-211
- Hunt SA: Complications of heart transplantation. *J Heart Transplant* 1983;3:70-74
- Fish RD, Nabel EG, Selwyn AP, Ludmer PL, Mudge GH, Kirshenbaum JM, Schoen FJ, Alexander RW, Ganz P: Responses of coronary arteries of cardiac transplant patients to acetylcholine. *J Clin Invest* 1988;8:21-31
- Nellessen U, Lee TC, Fischell TA, Ginsburg R, Masuyama T, Alderman EL, Schroeder JS: Effects of acetylcholine on epicardial coronary arteries after cardiac transplantation without angiographic evidence of fixed graft narrowing. *Am J Cardiol* 1988;62:1093-1097
- Hodgson JM, Marshall JJ: Direct vasoconstriction and endothelium-dependent vasodilation: Mechanisms of acetylcholine effects on coronary flow and arterial diameter in patients with nonstenotic coronary arteries. *Circulation* 1989;79:1043-1051
- Ludmer PL, Selwyn AP, Shook TL, Wayne RR, Mudge GH, Alexander RW, Ganz P: Paradoxical vasoconstriction induced by acetylcholine in atherosclerotic coronary arteries. *N Engl J Med* 1986;315:1046-1051
- Werns SW, Walton JA, Hsia HH, Nabel EG, Sanz ML, Pitt B: Evidence of endothelial dysfunction in angiographically normal coronary arteries of patients with coronary artery disease. *Circulation* 1989;79:287-291
- Vita JA, Treasure CB, Nabel EG, McLenachan JM, Fish RD, Yeung AC, Vekshtein VI, Selwyn AP, Ganz P: Coronary vasomotor response to acetylcholine relates to risk factors for coronary artery disease. *Circulation* 1990;81:491-497
- Brown BG, Bolson EL, Petersen RB, Pierce CD, Dodge HT: The mechanisms of nitroglycerin action: Stenosis vasodilatation as a major component of the drug response. *Circulation* 1981;64:1089-1097
- Feldman RL, Pepine CJ, Conti CR: Magnitude of dilatation of large and small coronary arteries by nitroglycerin. *Circulation* 1981;64:324-332
- Stinson EB, Griep RB, Bieber CP, Shumway NE: Changes in coronary blood flow during rejection of the orthotopically transplanted canine heart. *J Thorac Cardiovasc Surg* 1972;63:854-864
- Salomon NW, Stinson EB, Griep RB, Shumway NE: Alterations in total and regional myocardial blood flow during acute rejection of orthotopic canine cardiac allografts. *J Thorac Cardiovasc Surg* 1978;75:542-547
- Foegh ML, Khirabadi BS, Rowles JR, Braquet P, Ramwell PW: The causal role of PAF and leukotrienes in acute cardiac allograft rejection in rats. *Pharmacol Res Commun* 1986;18(suppl):127-132
- Kosek JC, Chartrand C, Hurley EJ, Lower RR: Arteries in canine cardiac homografts: Ultrastructure during acute rejection. *Lab Invest* 1969;21:328-335
- Forbes RDC, Guttman RD, Gomersall M, Hibberd J: A controlled serial ultrastructural tracer study of first-set cardiac allograft rejection in the rat. *Am J Pathol* 1983;111:184-196
- Dumont L, Chartrand C: Coronary vascular reactivity after heart transplantation in dogs: Nitroglycerin-induced response. *J Heart Transplant* 1990;9:213-219
- Nishimura RA, Edwards WD, Warnes CA, Reeder GS, Holmes DR, Tajik AJ, Yock PG: Intravascular ultrasound imaging: In vitro validation and pathologic correlation. *J Am Coll Cardiol* 1990;16:145-154
- St Goar FG, Pinto FJ, Stadius ML, Fischell TA, Alderman EL, Popp RL: In vivo coronary intravascular ultrasound imaging: Correlation with angiography. *J Am Coll Cardiol* 1991;18:952-958
- St Goar FG, Pinto FJ, Alderman EL, Valentine HA, Popp RL: Intracoronary ultrasound in cardiac transplant recipients: In vivo evaluation of angiographically silent intimal thickening. *J Am Coll Cardiol* 1991;17(suppl A):102A
- Pinto FJ, St Goar FG, Chiang M, Popp RL, Valentine HA: Intracoronary ultrasound evaluation of intimal thickening in cardiac transplant recipients: Correlation with clinical characteristics. *J Am Coll Cardiol* 1991;17(suppl A):103A
- Billingham ME: Diagnosis of cardiac rejection by endomyocardial biopsy. *J Heart Transplant* 1981;1:25-30
- Fitzgerald PJ, St Goar FG, Kao AK, Connolly AJ, Pinto FJ, Popp RL, Yock PG: Intravascular imaging of coronary arteries: Is three layers the norm? *J Am Coll Cardiol* 1991;17(suppl A):217A



25. Pietro DA, Voelkel AG, Ray BJ, Parisi AF: Reproducibility of echocardiography: A study evaluating the variability of serial echocardiographic measurements. *Chest* 1981;79:29-32
26. Leung WH, Demopoulos PA, Alderman EL, Sanders W, Stadius ML: Evaluation of catheters and metallic catheter markers as calibration standard for measurement of coronary dimension. *Cathet Cardiovasc Diagn* 1990;21:148-153
27. Scoblionko DP, Brown BG, Mitten S, Caldwell JH, Kennedy JW, Bolson EL, Dodge HT: A new digital electronic caliper for measurement of coronary arterial stenosis: Comparison with visual estimates and computer-assisted measurements. *Am J Cardiol* 1984;53:689-693
28. Wilson RF, Laughlin DE, Ackell PH, Chilian WM, Holida MD, Hartley CJ, Armstrong ML, Marcus ML, White CW: Transluminal, subselective measurement of coronary artery blood flow velocity and vasodilator reserve in man. *Circulation* 1985;72:82-92
29. Tadaoka S, Kagiya M, Hiramatsu O, Ogasawara Y, Tsujioka K, Wada Y, Sawayama T, Kajiya F: Accuracy of 20-MHz Doppler catheter coronary artery velocimetry for measurements of coronary blood flow velocity. *Cathet Cardiovasc Diagn* 1990;19:205-213
30. Ross JJ Jr, Mintz GS, Chandrasekaran K: Transthoracic two-dimensional high frequency (7.5 MHz) ultrasonic visualization of the distal left anterior descending coronary artery. *J Am Coll Cardiol* 1990;15:373-377
31. Illiceto S, Marangelli V, Memmola C, Rizzon P: Transesophageal Doppler echocardiography evaluation of coronary blood flow velocity in baseline conditions and during dipyridamole-induced coronary vasodilation. *Circulation* 1991;83:61-69
32. Taams MA, Gussenhoven EJ, Cornel JH, The SHK, Roelandt JRTC, Lancee CT, Brand MVD: Detection of left coronary stenosis by transesophageal echocardiography. *Eur Heart J* 1988;9:1162-1166
33. Yock PG, Linker DT, Angelsen AJ: Two-dimensional intravascular ultrasound: Technical development and initial clinical experience. *J Am Soc Echocardiogr* 1989;2:296-304
34. Roelandt J, Serruys PW: Intraluminal real-time ultrasonic imaging: Clinical perspectives. *Inu J Card Imaging* 1989;4: 89-97
35. Potkin BN, Bartorelli AL, Gessert JM, Neville RF, Almagor Y, Roberts WC, Leon MB: Coronary artery imaging with intravascular high-frequency ultrasound. *Circulation* 1990;81: 1575-1585
36. Gussenhoven EJ, Essed CE, Lancee CT, Mastik F, Frietman P, Van Egmond FC, Reiber J, Bosch H, Van Urk H, Roelandt J, Bom N: Arterial wall characteristics determined by intravascular ultrasound imaging: An in vitro study. *J Am Coll Cardiol* 1989;14:947-952
37. Furchgott RF: Role of endothelium in responses of vascular smooth muscle. *Circ Res* 1983;53:558-573
38. Vanhoutte PM, Rimele TJ: Role of endothelium in the control of vascular smooth muscle function. *J Physiol (Paris)* 1983;78: 681-686
39. Porter KA, Caine RY, Zukoski CF: Vascular and other changes in 200 canine renal homotransplants treated with immunosuppressive drugs. *Lab Invest* 1964;13:809-824
40. Schütz A, Kemkes BM, Kugler Ch, Angermann C, Schad N, Rienmüller R, Fritsch S, Anthuber M, Neumaier P, Gokel JM: The influence of rejection episodes on the development of coronary artery disease after heart transplantation. *Eur J Cardiothorac Surg* 1990;4:300-308
41. Ryan TJ, Vekshtein VI, Yeung AC, Vita JA, Fish D, Mudge GH, Selwyn AP, Ganz P: Recovery of endothelial function in coronary arteries early after cardiac transplantation (abstract). *Circulation* 1990;82(suppl III):III-256
42. Brown BG, Bolson EL, Dodge HT: Dynamic mechanisms in human coronary stenosis. *Circulation* 1984;70:917-922
43. Johnson DE, Alderman EL, Schroeder JS, Gao SZ, Hunt S, DeCampli WM, Stinson E, Billingham M: Transplant coronary artery disease: Histopathologic correlations with angiographic morphology. *J Am Coll Cardiol* 1991;17:449-457
44. Gao SZ, Schroeder JS, Alderman EL, Hunt SA, Valantine HA, Wiederhold V, Stinson EB: Prevalence of accelerated coronary artery disease in heart transplant survivors: Comparison of cyclosporine and azathioprine regimens. *Circulation* 1989;80(suppl III):III-100-III-105
45. Johnson DE, Gao SZ, Schroeder JS, DeCampli WM, Billingham ME: The spectrum of coronary artery pathologic findings in human cardiac allografts. *J Heart Transplant* 1989;8:349-359
46. Billingham ME: Graft coronary disease: The lesions and the patients. *Transplant Proc* 1989;21:3665-3666

---

KEY WORDS • intravascular imaging • echocardiography • heart transplantation • coronary artery disease

**Nitroglycerin-induced coronary vasodilation in cardiac transplant recipients. Evaluation with in vivo intracoronary ultrasound.**

F J Pinto, F G St Goar, T A Fischell, M L Stadius, H A Valentine, E L Alderman and R L Popp

*Circulation*. 1992;85:69-77

doi: 10.1161/01.CIR.85.1.69

*Circulation* is published by the American Heart Association, 7272 Greenville Avenue, Dallas, TX 75231

Copyright © 1992 American Heart Association, Inc. All rights reserved.

Print ISSN: 0009-7322. Online ISSN: 1524-4539

The online version of this article, along with updated information and services, is located on the World Wide Web at:

<http://circ.ahajournals.org/content/85/1/69>

**Permissions:** Requests for permissions to reproduce figures, tables, or portions of articles originally published in *Circulation* can be obtained via RightsLink, a service of the Copyright Clearance Center, not the Editorial Office. Once the online version of the published article for which permission is being requested is located, click Request Permissions in the middle column of the Web page under Services. Further information about this process is available in the [Permissions and Rights Question and Answer](#) document.

**Reprints:** Information about reprints can be found online at:  
<http://www.lww.com/reprints>

**Subscriptions:** Information about subscribing to *Circulation* is online at:  
<http://circ.ahajournals.org/subscriptions/>