

# Detection of Coronary Atherosclerosis in Young Adult Hearts Using Intravascular Ultrasound

Frederick G. St. Goar, MD; Fausto J. Pinto, MD; Edwin L. Alderman, MD;  
Peter J. Fitzgerald, MD, PhD; Edward B. Stinson, MD;  
Margaret E. Billingham, MB, BS, FRCPath; and Richard L. Popp, MD

**Background.** Coronary atherosclerosis has been demonstrated in young adults by postmortem pathology. Angiographic evaluation of coronary disease in young adults is limited by ethical issues and the insensitivity of angiography for detecting early pathology. Catheter-based intracoronary ultrasound has proven useful both in detecting and quantitating coronary disease, but the ultrasound appearance of young, angiographically normal, coronary arteries has not been well defined.

**Methods and Results.** Twenty-five subjects were examined with intracoronary ultrasound within 1 month of cardiac transplantation. Mean age of the donor hearts was 28 years (range, 14–43 years). Measurements of an index of intimal thickening were obtained at four left anterior descending coronary artery sites in each patient. All study patients had angiographically normal coronary arteries. Ultrasound in 14 subjects demonstrated a three-layered appearance of the coronary vessel wall with a mean intimal index of  $0.16 \pm 0.07$ . The other 10 subjects, including all donors under the age of 25 years, had coronary vessel wall layers too thin to be imaged separately at the 30-MHz sound frequency. Five subjects had ultrasound evidence of focal intimal thickening greater than 500  $\mu\text{m}$ . The donors of these hearts each had risk factors for coronary artery disease. Two subjects died within 5 weeks of their ultrasound study. Histological measurements of the vessel wall layers were similar to the corresponding ultrasound values.

**Conclusions.** This study provides a reference for the intravascular ultrasound appearance of young adult coronary arteries and confirms pathology findings that young subjects with angiographically normal vessels have a range of coronary intimal thickening, which includes occasional evidence of focal, early atheromatous lesions. (*Circulation* 1992;86:756–763)

**KEY WORDS** • intracoronary ultrasound • coronary artery disease

Understanding the natural history and pathogenesis of atherosclerosis has progressed significantly since the landmark necropsy report of substantial coronary disease in young American soldiers killed during the Korean War.<sup>1</sup> Subsequent autopsy studies correlated the presence of coronary artery plaques and coronary intimal thickening with the age of the individual and suspected atherogenic risk factors and confirmed that atherosclerotic changes are often present at an early age.<sup>2</sup>

Selective contrast coronary arteriography currently is considered the most sensitive and specific clinically applicable technique for anatomic detection of atherosclerosis. Although quantitative arteriography provides precise lumen measurements, it has been challenged by

studies demonstrating the underestimation of atheroma severity inherent in an imaging method, which provides only a longitudinal silhouette of the vessel lumen.<sup>3–5</sup>

Intracoronary ultrasound is a new technique for real-time two-dimensional visualization of coronary arteries. A miniaturized ultrasound transducer mounted on the tip of a catheter delineates vessel wall thickness and morphology and provides measurements of lumen dimensions.<sup>6–8</sup> Recent studies using in vitro and in vivo human vessels have shown good correlations with pathology and angiographic studies.<sup>9–15</sup> In vivo intracoronary ultrasound studies to date have been performed in patients undergoing arteriography for suspected or proven coronary artery disease, but the use of this group to determine the ultrasound appearance of a normal coronary artery is not valid. Therefore, it is important to define the appearance of normal coronary arteries in hearts not suspect for atherosclerosis. New cardiac transplant recipients present a unique group in which it is possible to image coronary arteries of young donor hearts, therefore overcoming ethical problems of imaging coronary arteries in normal young people.

In this article, we present in vivo intracoronary ultrasound studies performed in recent cardiac transplant recipients with young donor hearts and angiographically normal coronary arteries.

From the Division of Cardiovascular Medicine (F.G.S.G., F.J.P., E.L.A., P.J.F., R.L.P.), Department of Cardiothoracic Surgery (E.B.S.) and Department of Pathology (M.E.B.), Stanford University School of Medicine, Stanford, Calif.

F.J.P. is the recipient of a Fellowship Award from Fundação Calouste Gulbenkian (Lisbon, Portugal).

Some of the authors of this paper (F.G.S., P.J.F., R.L.P.) serve as consultants to Cardiovascular Imaging Systems, Inc. and hold equity interests in the company.

Address for reprints: Richard L. Popp, MD, Division of Cardiovascular Medicine, Stanford University School of Medicine, Stanford, CA 94305.

Received January 9, 1992; revision accepted May 28, 1992.

**TABLE 1. Clinical Data and Mean Intimal Thickness for 25 Hearts Studied With Intracoronary Ultrasound Early After Cardiac Transplantation**

Patient	Recipient age and sex	Indication for transplant	Donor age and sex	Intimal index	Cardiac risk factors	Rejection	Ischemic time (minutes)
1	49 F	ID	23 M	NM	...	...	169
2	55 M	IS	34 M	0.11	...	...	172
3	61 M	ID	26 M	NM	FH	††	126
4	56 F	ID	22 F	NM	...	††	88
5	48 M	IS	25 M	0.12	...	...	138
6	57 M	ID	43 M	0.10	...	††	182
7*	41 M	ID	43 M	0.31	Tob	††	145
8†	35 M	ID	28 M	0.15	...	...	171
9†	56 M	ID	37 F	0.13	...	...	210
10	47 M	ID	25 M	0.15	...	...	160
11	35 M	IS	17 M	NM	FH	...	175
12*	51 M	IS	38 M	0.20	FH, Hpt	...	172
13	60 M	IS	21 M	NM	Tob	...	135
14	52 F	ID	15 F	NM	...	...	204
15	54 M	ID	17 M	NM	...	...	155
16	29 M	IS#	27 M	0.16	Tob	...	200
17	47 F	IS	34 M	NM	...	...	123
18*	48 M	ID	29 M	0.33	Tob	††	132
19	57 M	ID	17 M	NM	Tob	...	155
20	44 M	IS	35 F	0.12	...	...	185
21*	60 M	IS	33 M	0.19	Tob	...	194
22	59 M	IS	33 M	0.11	Tob	...	238
23	44 M	IS	26 M	0.11	...	...	162
24	19 M	ID	14 M	NM	...	...	189
25*	50 F	ID	30 F	0.19	FH, Hpt	...	118

\*Patients with focal intimal thickening  $>500 \mu\text{m}$ ; †, patients who died (pathology); ID, idiopathic dilated cardiomyopathy; IS, ischemic cardiomyopathy; #, redo transplantation; NM, not measurable; FH, family history of heart disease; Tob, smoking history; Hpt, history of hypertension; ††, evidence of moderate or severe cardiac rejection on endomyocardial biopsy taken at the time of the ultrasound study; Ischemic time, period of ischemia during transplantation.

## Methods

### Patients

Twenty-five consecutive cardiac recipients were studied with intracoronary ultrasound during a routine baseline angiogram performed immediately before or shortly after the first posttransplantation hospital discharge (mean time from transplant,  $24 \pm 13$  days) as part of an investigation of accelerated graft coronary disease in cardiac transplant patients.<sup>16</sup> The recipient study population included 20 men and five women with a mean age of  $48 \pm 9$  years. The mean age of the donor hearts was  $28 \pm 8$  years (20 men, five women). Information about donor hearts was obtained by reviewing medical charts and data provided by the transplant registry. Clinical data are shown in Table 1. The donors were young and died of unanticipated causes. Risk factor data obtained for all donors included family history of early coronary disease, history of tobacco use, diabetes mellitus, or hypertension, as well as perioperative ischemic time and histological evidence of cardiac rejection at the time of the ultrasound study. No information was available on donor serum lipid status. All participants gave informed consent to the protocol approved by the Committee for the Protection of Human Subjects in Research at Stanford University Medical Center.

### Ultrasound Imaging Procedure

Intracoronary imaging is provided by a high-frequency 30-MHz ultrasound transducer enclosed within an acoustic housing on the tip of a 5F (1.7 mm) flexible 135-cm-long catheter (CVIS Inc., Sunnyvale, Calif.). The ultrasound beam is reflected against an angulated mirror rotating at 1,800 revolutions per minute, which creates a  $360^\circ$  imaging plane perpendicular to the catheter (Figure 1). A flexible drive cable through the length of the catheter is connected to a motor at the distal end, which drives the mirror. At focal depth, axial resolution of the image is  $150 \mu\text{m}$  and lateral resolution is  $200 \mu\text{m}$ . The radius of penetration is approximately 5 mm. Images are acquired at 30 frames per second and recorded on 0.5-in. videotape for subsequent off-line analysis. The imaging catheter has a lumen that accommodates an 0.014-in. coronary guidewire, which exits the catheter centrally, distal to the transducer via a flexible tapered tip. This allows for manipulation of the ultrasound catheter in a coronary artery in a fashion similar to coronary balloon angioplasty systems.

After anticoagulation with 10,000 units heparin i.v. and nitroglycerin 0.4 mg s.l., a complete coronary angiography study was performed using multiple orthogonal views. Subjects were then scanned, using fluoroscopic guidance, with the ultrasound catheter from

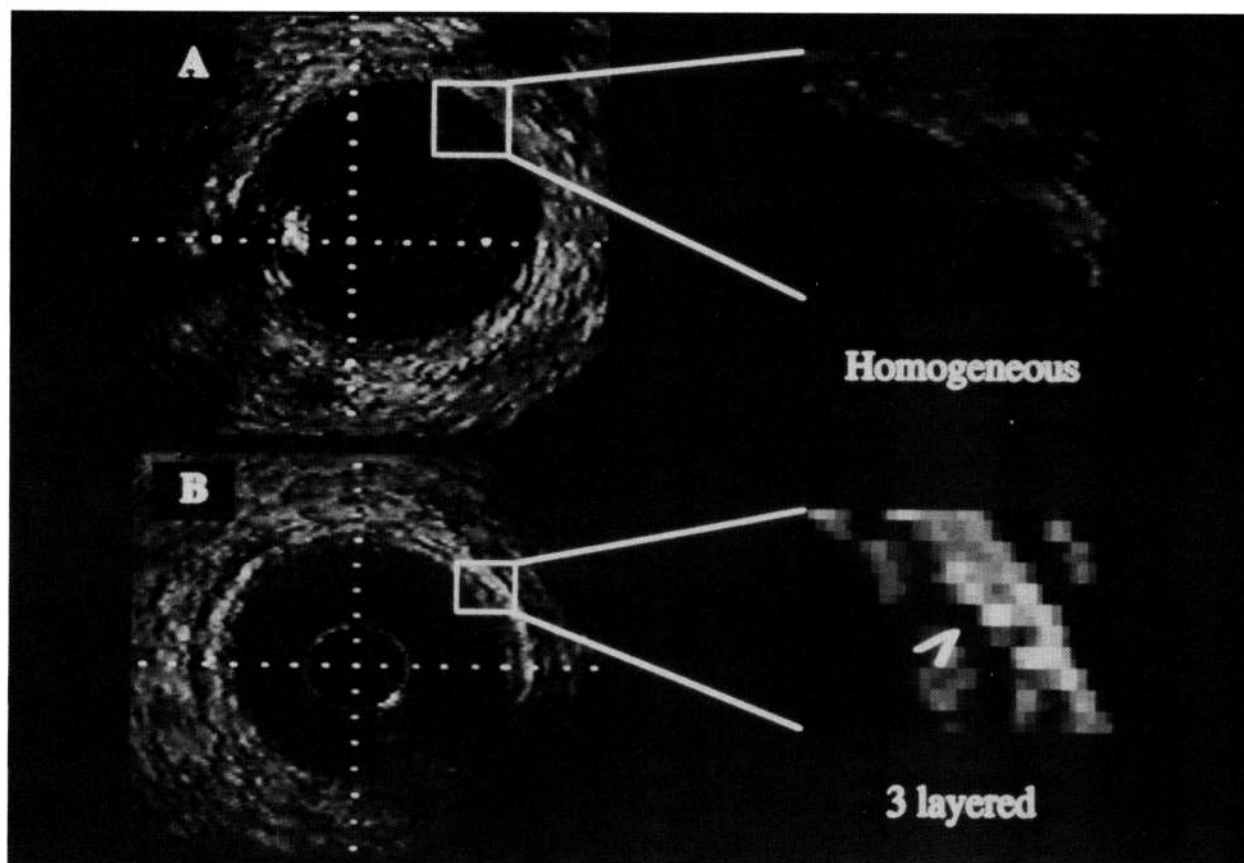


FIGURE 1. Panel A: Intravascular ultrasound image from the left anterior descending coronary artery of a patient with a 17-year-old donor heart. The dark black circle in the center of the image is the catheter. The perpendicular grid of tick marks are at 0.5-mm intervals. The circular vessel wall and surrounding tissue appear acoustically homogenous. The bright shadow at 9 o'clock on the edge of the catheter is an artifact caused by a mechanical strut and coronary guidewire. Panel B: Ultrasound image from the left anterior descending coronary artery from a 33-year-old donor showing thin but visible concentric three-layered appearance of the vessel wall. The white arrow indicates the hypoechoic medial layer.

the ostium of the left main coronary artery to the mid portion of the left anterior descending coronary artery (LAD), avoiding vessel segments less than 2 mm in diameter. Six subjects also had their circumflex artery imaged, and in four subjects the right coronary artery also was examined. Besides continual scanning of the vessel, four distinct LAD locations per patient were determined for precise ultrasound measurements. These sites were determined angiographically and were separated by at least 1 cm but less than 2 cm. Measurement sites were selected where the lumen was circular, thus avoiding areas of vessel bifurcations and side branches. Image quality was consistently good in vessels larger than 2 mm in diameter, and therefore this was not a factor in site selection.

#### Ultrasound Analysis

Ultrasound images were digitized onto a  $512 \times 512 \times 8$  bit matrix in 34-frame sequences, obtained at 30 frames per second, by an image-processing computer (Dextra Medical Inc., Lakewood, Calif.) dedicated to echocardiographic analysis. All patients had resting heart rates above 60 beats per minute (mean,  $84 \pm 11$  beats per minute), and thus at least one cardiac cycle was digitized. The largest lumen from the digitized cardiac cycle was obtained for analysis. Measurements were per-

formed by two investigators (F.S.G. and F.J.P.). The lumen/vessel wall interface was traced by planimetry, and when visible, the external border of the intimal layer, the intimal/media interface, was also planimtered. This allowed calculation of an index of intimal thickening, which is defined as the intimal area divided by the intima plus the lumen area (i.e., relative intima area) (Figure 2). All real-time images were reviewed for areas of significant focal intimal thickening (defined as  $>500 \mu\text{m}$ ) as well as for discrete echodense calcium or fibrosis. Coronary angiograms were examined for evidence of coronary artery disease by an investigator (E.L.A.) blinded to the ultrasound data.

#### Interobserver and Intraobserver Variability

Five patients (19 sites) were selected randomly and measured by one observer at two separate times and once by a second observer. These measurements then were used to evaluate intraobserver and interobserver variability. These were expressed as a linear regression between the two observations and as a percent error, which was derived as the absolute difference between observations.<sup>17</sup>

#### Pathology

Two subjects died from systemic sepsis 34 and 37 days after their ultrasound studies. Their deaths were in no

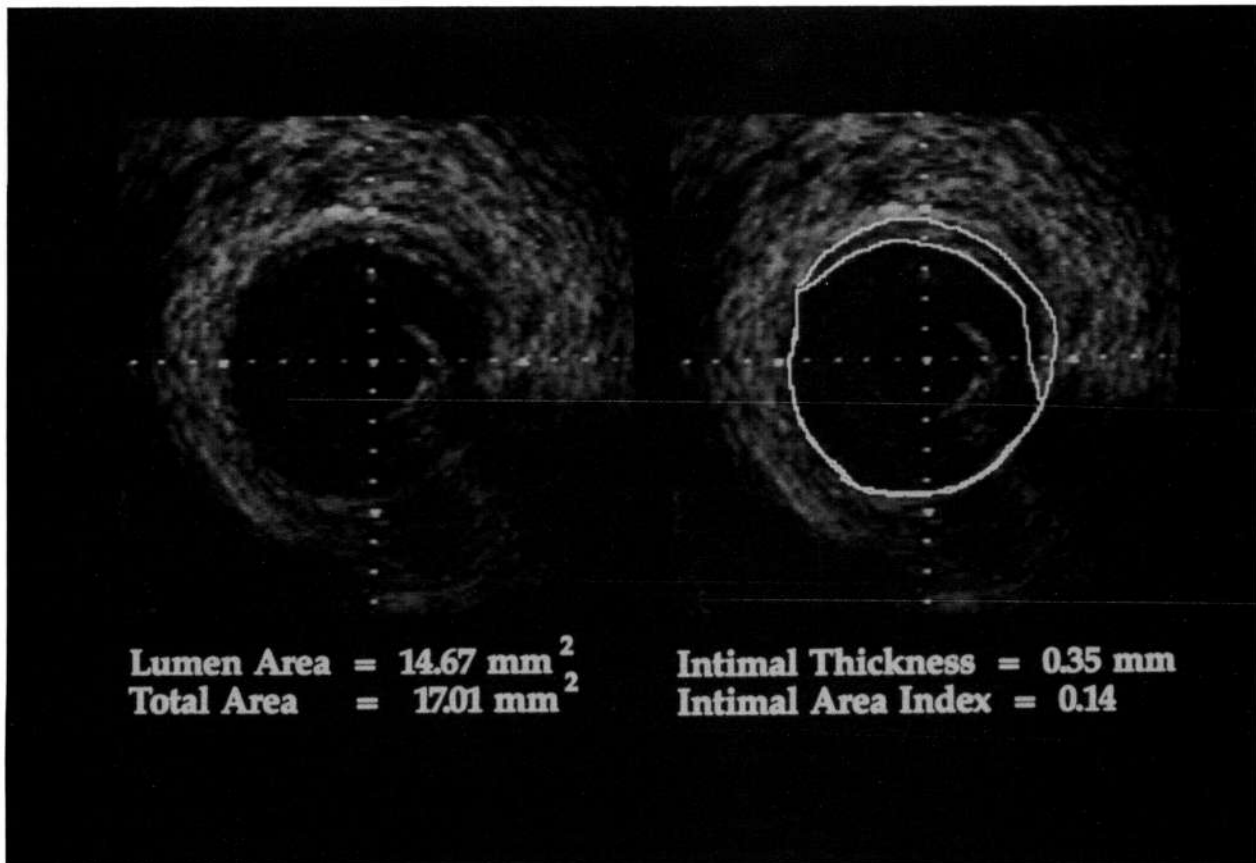


FIGURE 2. Ultrasound image from a left anterior descending coronary artery demonstrating the method of measurement of intimal thickness. The vessel-lumen interface and any intima-media interface are separately planimetered. This allows for the calculation of lumen area, total lumen plus intima area, and an intimal area index obtained by dividing intimal area by the total area.

way related to their angiographic or ultrasound studies. The three major epicardial coronary arteries and their largest branches were dissected intact from these two allografts. The arteries were not perfusion fixed. The vessels were scanned for gross evidence of early atherosclerosis, and selected arterial segments from each heart were processed routinely for light microscopy. Tissue sections cut at 4- $\mu$ m thickness were stained with hematoxylin and eosin and elastic van Gieson stains. Representative sections from the LAD where the ultrasound study was performed were examined with a light microscope fitted with a calibrated eyepiece scale. The mean thickness of the intima was determined by taking an average of six radial measurements around the vessel circumference. The ultrasound images from the corresponding sites were quantitated in a similar fashion by taking the mean of six radial measurements of intimal thickness.

Right ventricular endomyocardial biopsies were performed at the time of each ultrasound study. At least four specimens of right ventricular tissue were obtained from each patient and graded for myocardial rejection according to the Billingham criteria.<sup>18</sup>

### Results

High resolution ultrasound images were obtained without complications in all 25 subjects. In 10 of the patients, the vessel wall had a completely homogeneous

appearance on the ultrasound image throughout the examined area. The lumen/wall acoustic interface defined the luminal edge of the vessel, but neither the components of the wall nor the elastic laminae could be appreciated. The mean donor age of these patients was 20 years. All donors under the age of 25 years had a homogenous nonlayered vessel wall as demonstrated by ultrasound. In the other 15 studies (mean donor age, 32 years), a three-layered appearance was discernible in areas of the vessel wall corresponding to the intima, a homogenous hypoechoic media, and a more echogenic adventitia. Mean intimal indexes of the four LAD sites are shown in Table 1. The mean intimal index in the 15 patients with a visible intima was  $0.16 \pm 0.07$ .

In five subjects, areas of markedly eccentric intimal thickening greater than 500  $\mu$ m were noted in the LAD. The circumflex and right coronary arteries were also imaged in three of these patients. Intracoronary ultrasound demonstrated multiple areas of discrete intimal thickening and increased echodensity in each of the vessels examined. Four of the hearts with focal ultrasound abnormalities came from male donors aged 29, 33, 38, and 43 years and who each had risk factors for early coronary artery disease; one had hypertension and the other three were heavy smokers. The fifth heart with focal thickening came from a 30-year-old woman with poorly controlled hypertension and a history of signifi-

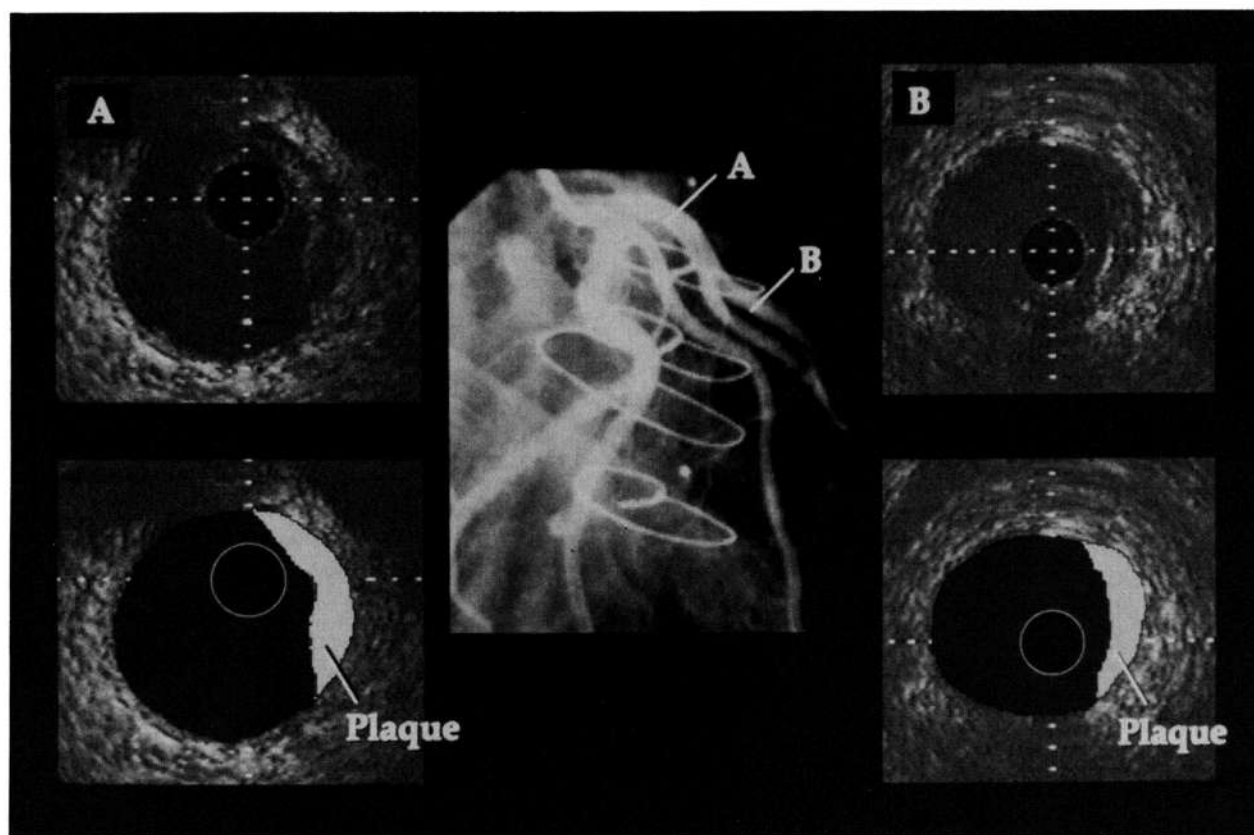


FIGURE 3. Normal angiogram and two representative ultrasound images from the left anterior descending coronary artery (LAD), site A and site B, in a transplant recipient. The two schematics below the ultrasound images depict the focal, eccentric plaques shown by ultrasound. The heart came from a 29-year-old donor who smoked two packs of cigarettes a day for 15 years.

cant tobacco use who died from a ruptured cerebral aneurysm.

The 43-year-old male donor with ultrasound abnormalities had undergone screening angiography before the explantation of his heart; this is a procedure that is routinely performed in all potential donors over 40 years old. His coronaries were angiographically normal in the pretransplant study and had a similar appearance to the posttransplant study. The other three donors also had completely normal coronary arteriograms performed at the time of their ultrasound studies. The abnormal 29-year-old donor heart came from an obese inactive man who had smoked two packs of cigarettes per day since the age of 9 years. Intracoronary ultrasound evaluation of his angiographically normal LAD demonstrated multiple areas of discrete intimal proliferation up to 700- $\mu$ m thick (Figure 3). The risk factors of the 20 donors who did not demonstrate focal intimal thickening are presented in Table 1.

Gross examination of the coronary arteries from the two subjects who died within 37 days of their ultrasound studies revealed no significant fatty streaks, atheromatous plaques, or evidence of early coronary artery disease. The donor age of these hearts was 28 years and 37 years. Microscopic measurements from two sites in the nonpressure-fixed proximal LAD revealed a mean intimal layer of 123  $\mu$ m with a range from 70 to 190  $\mu$ m and 145  $\mu$ m with a range from 60 to 210  $\mu$ m. The mean ultrasound measurements of intimal thickness at these

sites were 67  $\mu$ m with a range from 0 to 200  $\mu$ m and 120  $\mu$ m with a range from 0 to 200  $\mu$ m. (Figure 4).

The measurements performed on the ultrasound images to assess interobserver variability demonstrated good reproducibility. The interobserver variability for the intimal index was 9% ( $r=0.87$ ), and the intraobserver variability was 7% ( $r=0.86$ ).

The endomyocardial biopsy specimens obtained at the time of the ultrasound studies revealed evidence of cardiac rejection in five of the 24 patients. There was no significant increase in the thickness of the intima in the subjects with rejection. Duration of ischemia occurring at the time of transplantation also did not correlate significantly with the ultrasound-measured mean intimal thickness (Table 1).

### Discussion

Accelerated graft coronary disease is a major cause of morbidity and mortality in cardiac transplant recipients.<sup>19,20</sup> At Stanford University Medical Center, coronary artery disease accounts for 23% of deaths in patients who live longer than 1 year and 60% of retransplantation procedures.<sup>21,22</sup> This vascular disease may present with dramatic clinical sequelae and often progresses rapidly. Because the cardiac allograft remains functionally denervated, transplant recipients typically do not experience discomfort of angina pectoris. Annual surveillance coronary arteriograms, including a baseline study before posttransplantation hospital discharge, have thus been performed at Stanford since



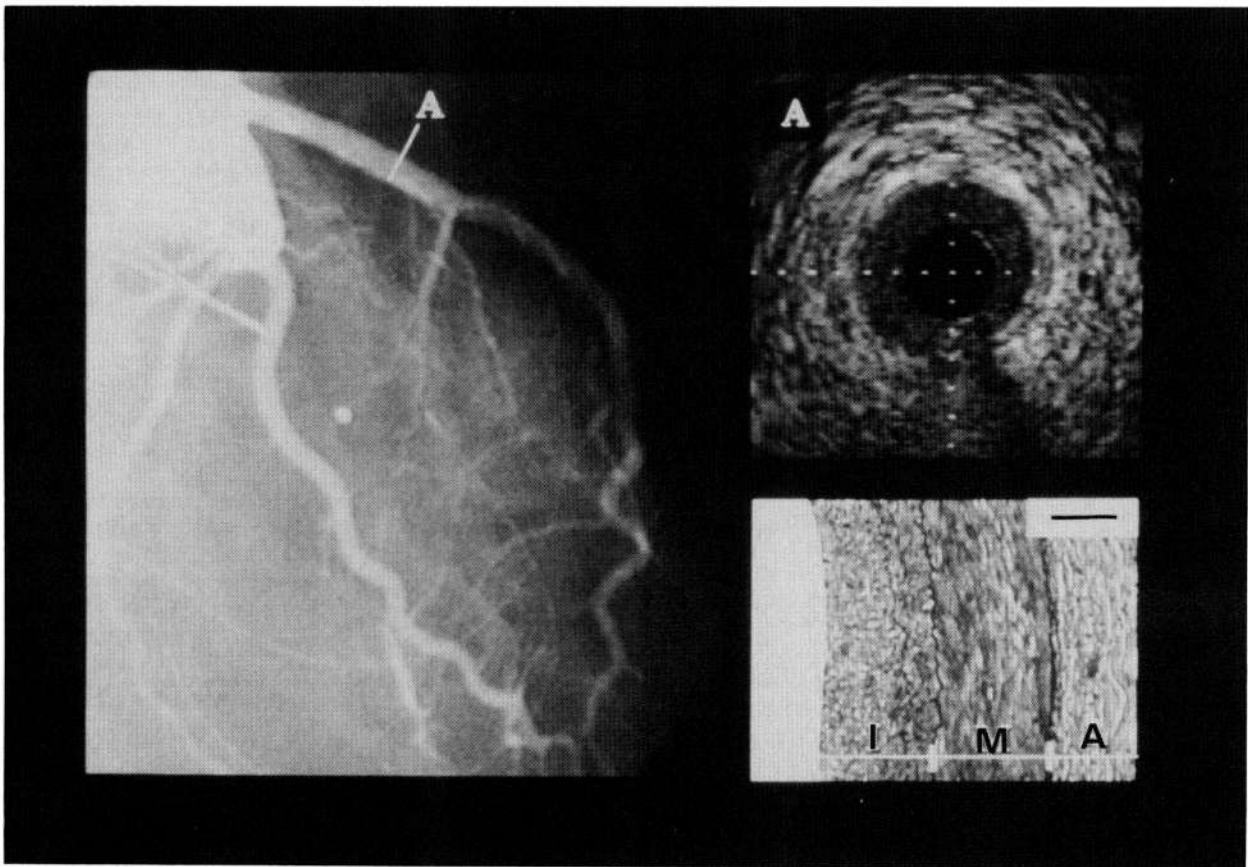


FIGURE 4. Coronary angiogram from a 37-year-old donor heart whose recipient died 34 days after the study. Panel A: An ultrasound image from the proximal left anterior descending coronary artery (site A marked on angiogram). A thin layering of the vessel wall is best appreciated on the image between 11 and 1 o'clock and at 3 o'clock. Lower right panel: A high-power microscopic view of the vessel wall from the same location demonstrating the intima (I), media (M), and adventitia (A). The mean microscopic measurement of the intima from this site was 145  $\mu\text{m}$  and the mean ultrasound measurement was 120  $\mu\text{m}$ . (bar=100  $\mu\text{m}$ ).

shortly after the transplant program was initiated. The baseline studies early after transplantation provide the opportunity to observe intracoronary ultrasound images in young hearts that are putatively normal.

This study examined 25 young adult hearts with the goal of providing the intravascular ultrasound definition of a normal coronary artery image. Intracoronary ultrasound showed in this patient group a wide variation in the thickness of the coronary artery intimal layer as well as isolated examples of coronary morphology that were suggestive of early atheromatous disease.

Original publications on the intravascular ultrasound appearance of normal muscular vessels showed the wall as having three visible discrete layers: a hyperechoic intima and internal elastic lamina, a dark hypoechoic band representing the homogenous smooth muscle of the media, and the echodense adventitia.<sup>9,11-13</sup> These studies were initially performed in peripheral vessels of elderly patients and then in coronary arteries of patients with suspected or proven coronary artery disease. Our results suggest that in these earlier reports the intima probably was thickened such that there were discrete layers with visible boundaries on the ultrasound image. Pathology investigations, including the Korean War and Vietnam War studies, have demonstrated a wide prevalence of coronary atherosclerosis in young adult populations.<sup>1,23</sup> Velican and Velican<sup>24</sup> performed a pathol-

ogy study showing that coronary intimal thickness progresses with age, which ranged from unmeasurable in neonates to a mean of 253  $\mu\text{m}$  in men aged 36–40 years (Table 2). In their study, the range of intimal thickness in men up to 30 years old was below 150  $\mu\text{m}$ , which is the reported axial resolution of a 30-MHz mechanical intracoronary ultrasound catheter.<sup>25</sup> In the present study, no donor heart under the age of 25 years had ultrasound evidence of layering of the coronary

TABLE 2. Intimal Thickening of Left Anterior Descending Coronary Artery in Male Subjects by Age\*

Age groups (years)	Case studies (No.)	Intima thickness ( $\mu\text{m}$ )	
		Mean	Range
Neonates	102	61	0–112
1–5	28	78	12–165
6–10	30	96	46–188
11–15	28	138	68–203
16–20	26	161	89–235
21–25	28	205	103–276
26–30	30	219	115–277
31–35	28	238	185–301
36–40	28	253	183–347

\*Velican et al.<sup>24</sup>

artery vessel wall. Previous in vitro intravascular ultrasound studies in normal vessels have demonstrated a three-layered appearance even with a single-cell-layer thick intima.<sup>26,27</sup> The proposed explanation for the intense echo reflection is that it is caused by the internal elastic membrane.<sup>26,27</sup> In vitro, this could be true as the internal elastic membrane may be corrugated. The lack of layering in the young donor hearts in the present in vivo evaluation suggests that, at least with the mechanical ultrasound system used in this study, layering cannot be appreciated despite a presumably intact internal elastic lamina. Advances in ultrasound technology or other presently available ultrasound systems may offer improved resolution. Progressive intimal thickening with age therefore probably explains the appearance of visible layers in the majority of donors over age 25 examined in this study. The lack, or minimal amount, of discrete layering of the vessel walls is the intravascular ultrasound appearance of young, morphologically normal, coronary arteries.

Although accelerated graft coronary disease is an aggressive process in the transplant population, histologically or ultrasonically it probably will not be present within the first two months after transplantation and thus probably does not play a significant role in the measurements and morphological observations made in this study. Acute rejection could interfere with wall measurements by producing vascular tissue edema. Regression analysis did not demonstrate presence of rejection as a contributing factor.

The five subjects demonstrating intracoronary ultrasound evidence of focal, marked intimal thickening, and echo-dense abnormalities each had cardiac risk factors for early coronary disease. Pathology/ultrasound correlation studies have shown vessels with similar ultrasound appearances to have fibrous and/or calcified atheromatous lesions,<sup>10</sup> which confirms that despite angiographically normal appearing vessels, intravascular ultrasound is able to demonstrate early morphological evidence of coronary artery disease.

Eighteen of the study subjects had ultrasonic imaging of only the LAD. Subjects in this group may have had isolated disease in the circumflex or right coronary artery that were missed. When accelerated intimal thickening does occur, it typically presents in all three major coronary vessels.<sup>28</sup> This is supported by the finding of focal intimal proliferation in the circumflex and right coronaries in three of the subjects in this study who had ultrasound evidence of LAD intimal thickening.

In the two patients who died within 37 days of their ultrasound studies, microscopic measurements of the non-pressure-fixed LAD revealed intimal layers thicker than the 150- $\mu$ m resolution of the ultrasound catheter. In each case, an intima was evident on the in vivo ultrasound study in the corresponding location. The pathology and ultrasound measurements were similar, and pathology examination confirmed a wide range of intimal thickness within each cross section. It is not surprising that the mean intimal thickness measurements on pathology specimens are slightly larger than those derived by ultrasound as there were areas around the diameter of the lumen on the ultrasound images with a homogenous wall and a nonmeasurable intima. The larger pathology than ultrasound measurements

from corresponding sites is also possibly caused by the increase in vessel wall thickness that occurs in nondissected pathology specimens. The microscopic measurements of intimal thickness, in comparison to previous pathology data, were not excessive for the donor heart's age.<sup>24</sup>

The reproducibility of intravascular ultrasound for measuring thickness of the intimal layer has been previously reported and is good with an interobserver variability, expressed as a percent error, of 5.6% and a correlation coefficient of 0.98.<sup>15,16</sup> This study has greater variability probably because defining and measuring wall layers in these young minimally or nondiseased vessels is significantly more difficult than in older diseased arteries.

In the present study, an index of intimal thickening was used as a quantitative measurement of intimal proliferation. Although this may be a useful marker for serial studies, it has potential limitations by not differentiating between significant focal eccentric intimal proliferation and mild concentric thickening. A recently published classification of intimal thickening, based on the degree of vessel circumference involved and absolute thickness, may help to overcome this limitation.<sup>16</sup>

### Conclusions

Intravascular ultrasound successfully images coronary artery abnormalities before there is angiographic evidence of atherosclerotic disease. In young morphologically normal hearts, the intimal and medial layers are often thin and below the resolution capability of the ultrasound imaging system used in this study. With advancing age, physiological intimal and medial thickening leads to a three-layered ultrasound appearance of the vessel wall. This study confirms that young adults have a range of coronary intimal proliferation. Twenty-five young, angiographically normal hearts, which had undergone rigorous screening to becoming transplant donors, had a broad range of ultrasound-measured intimal thickness, and five had ultrasound evidence of focal early atheromatous changes. This confirms pathology studies by showing, in vivo, coronary atheromatous changes in a young adult population in the 1990s. Intravascular ultrasound may be a useful and effective tool for detection of early coronary artery disease and is a possible screening method for coronary atherosclerosis in select groups, which includes potential heart donors.

### Addendum

Since original submission of the manuscript we have studied sixteen more patients, thus increasing our population to 41 patients. Five more hearts showed evidence of focal intimal thickening for a total of 10 of 41 patients (24%). The donors of these five hearts were all over 32 years old (32, 36, 42, 43, and 45 years), and all had at least one risk factor for coronary disease (three were smokers, one had hypertension, and one had family history of coronary heart disease). These findings in these additional patients confirm our findings reported in the present study.

### References

- Enos WF, Holmes RH, Beyer J: Coronary disease among United States soldiers killed in action in Korea. *JAMA* 1953;152:1090-1093 (*JAMA* 1986;256:2859-2862)

2. Solberg LA, Strong JP: Risk factors and atherosclerotic lesions: A review of autopsy series. *Arteriosclerosis* 1983;3:187-198
3. Schwartz JN, Kong Y, Hackel DB, Bartel AG: Comparison of angiographic and postmortem findings in patients with coronary artery disease. *Am J Cardiol* 1975;36:174-178
4. Hutchins GM, Buckley BH, Ridolfi RL, Griffith LSC, Lohr FT, Piasio MA: Correlation of coronary arteriograms and left ventriculograms with post mortem studies. *Circulation* 1977;56:32-37
5. Arnett RN, Isner JM, Redwood D: Coronary artery narrowing in coronary heart disease: Comparison of cineangiographic and necropsy findings. *Ann Intern Med* 1979;36:174-178
6. Yock PG, Johnson EL, Linker DT: Intravascular ultrasound: Development and clinical potential. *Am J Cardiac Imaging* 1988;2: 185-193
7. Pandian NG, Weintraub A, Schwartz SL: Intravascular and intracardiac ultrasound imaging: Current research and future directions. *Echocardiography* 1990;7:377-387
8. Coy KM, Maurer G, Siegel RJ: Intravascular ultrasound imaging: A current perspective. *J Am Coll Cardiol* 1991;18:1811-1823
9. Gussenhoven WJ, Essed CE, Lancee C, Mastik F, Fritman P, Van Egmond FC, Rieber J, Bosch H, Van Urk H, Roelandt J, Bom N: Arterial wall characteristics determined by intravascular ultrasound imaging: An in vitro study. *J Am Coll Cardiol* 1989;14: 947-952
10. Tobis JM, Mallery J, Mahon D, Lehmann K, Zalesky P, Griffith J, Gessert J, Moriuchi M, McRae M, Dwyer ML, Greep N, Henry WL: Intravascular ultrasound imaging of human coronary arteries in vivo: Analysis of tissue characterization with comparison to in vitro histological specimens. *Circulation* 1991;83:913-926
11. Nishimura RA, Edwards WD, Warnes CA, Reeder GS, Holmes DR, Tajik AJ, Yock PG: Intravascular ultrasound imaging: In vitro validation and pathologic correlation. *J Am Coll Cardiol* 1990;16: 145-154
12. Pandian NG, Kreis A, Brockway B, Isner JM, Sacharoff A, Boleza E, Caro R, Muller D: Ultrasound angioscopy: Real-time, two-dimensional, intraluminal ultrasound imaging of blood vessels. *Am J Cardiol* 1988;62:493-494
13. Nissen SE, Grines CL, Gurley JC, Sublett K, Haynie D, Diaz C, Booth DC, DeMaria AN: Application of a new phased-array ultrasound imaging catheter in the assessment of vessel dimensions: In vivo comparison to cineangiography. *Circulation* 1990;81:660-666
14. Davidson CJ, Sheikh KH, Harrison JK, Harrison JK, Himmelstein SI, Leithe ME, Kisslo KB, Bashore TM: Intravascular ultrasonography versus digital subtraction angiography: A human in vivo comparison of vessel size and morphology. *J Am Coll Cardiol* 1990;16:633-636
15. St. Goar FG, Pinto FJ, Alderman EL, Fitzgerald PJ, Stadius ML, Popp RL: Intravascular ultrasound imaging of angiographically normal coronary arteries: An in vivo comparison with quantitative angiography. *J Am Coll Cardiol* 1991;18:952-958
16. St. Goar FG, Pinto FJ, Alderman EL, Valentine HA, Schroeder JS, Gao SZ, Stinson EB, Popp RL: Intracoronary ultrasound in cardiac transplant recipients: In vivo evidence of "angiographically silent" intimal thickening. *Circulation* 1992 (in press)
17. Pietro DA, Voelkel AG, Ray BJ, Parisi AF: Reproducibility of echocardiography: A study evaluating the variability of serial echocardiographic measurements. *Chest* 1981;79:29-32
18. Billingham ME: Diagnosis of cardiac rejection by endomyocardial biopsy. *Heart Transplant* 1981;1:25-30
19. Cooper DKC, Novitsky D, Hassoulas J, Barnard CN: Heart transplantation: The South African experience. *Heart Transplant* 1982; 2:78-84
20. Billingham ME: Cardiac transplant atherosclerosis. *Transplant Proc* 1987;19(suppl 5):19-25
21. Macvick JA, Oyer PE, Stinson EB, Jamieson SW, Baldwin JC, Schumway NE: Four-year experience with cyclosporine for heart and heart-lung transplantation. *Transplant Proc* 1985;17:97-101
22. Gao SZ, Schroeder JS, Hunt S, Stinson EB: Retransplantation for accelerated coronary vascular disease in heart transplant recipients. *Am J Cardiol* 1988;62:867-881
23. McNamara JJ, Molot MA, Stremple JF, Cutting RT: Coronary artery disease in combat casualties in Vietnam. *JAMA* 1971;216: 1185-1187
24. Velican D, Velican C: Comparative study on age-related changes and atherosclerotic involvement of the coronary arteries of male and female subjects up to 40 years of age. *Atherosclerosis* 1981;38: 39-50
25. Fitzgerald PJ, St. Goar FG, Kao AK, Connolly AJ, Pinto FJ, Popp RL, Yock PG: Intravascular ultrasound imaging of coronary arteries: Is three layers the norm? *J Am Coll Cardiol* 1991;17,N2:217A
26. Linker DT, Yock PG, Groeninsaeether A, Johansen E, Angelsen BAJ: Analysis of backscattered ultrasound from normal and diseased arterial wall. *Int J Card Imag* 1989;4:177-185
27. Barzilai B, Saffitz JE, Miller JG, Sobel BE: Quantitative ultrasonic characterization of the nature of atherosclerotic plaques in human aorta. *Circ Res* 1987;60:459-463
28. Roberts WC, Potkin BN, Solu DE, Reddy SG: Mode of death, frequency of healed and acute myocardial infarction, number of major epicardial coronary arteries severely narrowed by atherosclerotic plaque, and heart weight in fatal atherosclerotic coronary artery disease: Analysis of 889 patients studied at necropsy. *J Am Coll Cardiol* 1990;15:196-203