

CASE REPORT

A Challenging Case Of Pulmonary Arterial Hypertension: Never Judge By Appearances

Pedro Silvério António,¹ Manuel Silvério António,¹ Catarina Lopes Resende,¹ Tatiana Guimarães,¹ Daniel Cazeiro,² Yolanda Sá Pereira,¹ Fausto José Pinto,¹ Rui Plácido¹

*Centro Hospitalar Universitario Lisboa Norte EPE,¹ Lisboa – Portugal
Hospital de Santa Maria, Heart and Vessels Department,² Lisboa – Portugal*

Abstract

We report the case of a patient with symptomatic pulmonary hypertension (PH) associated with diffuse systemic sclerosis (SSc) whose initial assessment suggested a group 3 (clinical classification) PH. The patient had a history of drugs/toxins consumption, which contributed to the development of intrinsic pulmonary vascular disease. This changed the panorama towards the diagnosis of pulmonary arterial hypertension (PAH), with important therapeutic and prognostic implications. In fact, the excellent clinical, laboratory and hemodynamic response to therapy confirmed the hypothesis of a case of drug-associated PAH (DPAH) in a patient with diffuse SSc and lung disease. Considering the presence of DPAH, it was deemed necessary to assess acute vasoreactivity during right heart catheterization (RHC). If criteria were met, the clinical scenario may change towards a favorable and sustained clinical and hemodynamic response with oral calcium channel blockers. However, the response to inhaled nitric oxide was negative in our patient and the therapeutic strategy with dual oral combination therapy with tadalafil and ambrisentan was continued. After six-months of therapy the patient significantly improved, from a high to a low risk of one-year mortality.

Case report

A 60-year-old Caucasian female with a history of smoking and chronic obstructive pulmonary disease, and diffuse cutaneous systemic sclerosis (SSc)

Keywords

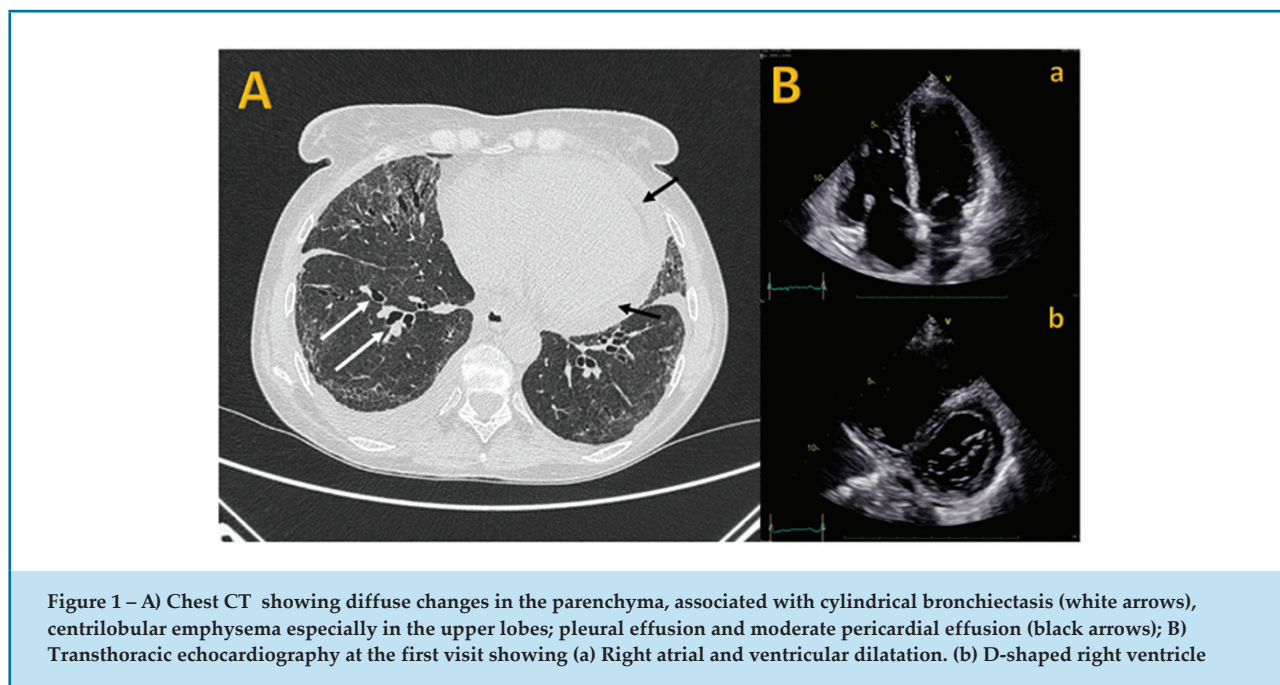
Connective Tissue; Pulmonary Arterial Hypertension; Case Reports.

diagnosed nine years ago, was referred to a pulmonary hypertension (PH) clinic due to progressive dyspnea (WHO functional class III), pre-syncope and high probability of PH by transthoracic echocardiogram (TTE). Physical examination revealed loud second heart sound, tricuspid systolic murmur, basal lung crepitations, bilateral peripheral edema and findings associated with SSc – proximal limb and trunk involvement with skin sclerosis, sclerodactyly, Raynaud's phenomenon and digital ulceration. She walked 337 meters on six-minute walk test (6MWT) with significant desaturation (nadir 77%). The TTE revealed dilated right heart cavities and right ventricular systolic dysfunction, severe secondary tricuspid regurgitation, elevated trans-tricuspid pressure gradient (64 mmHg) and moderate pericardial effusion (Figure 1A), with no left heart disease. NT-proBNP level was 5118 pg/mL, anti-topoisomerase I (anti-Scl-70) antibodies were present and anti-centromere antibodies were absent. A lung ventilation/perfusion scan excluded pulmonary embolism. Pulmonary function tests showed a moderate restrictive pattern [forced expiratory volume in one second of 84% predicted, forced vital capacity (FVC) of 77% predicted, total lung capacity of 69% predicted] and a severe reduction in pulmonary diffusing capacity for carbon monoxide (DLCO) of 26% predicted, with an FVC/DLCO ratio of 2.96.

Chest computed tomography (CT) demonstrated centrilobular emphysema, especially in the upper lobes, ground-glass opacities, subpleural sparing, honeycombing in basilar and peripheral predominant distribution, and reticular pattern with traction bronchiectasis (Figure 1B). Therapy with diuretics was started, and after optimization, the patient was referred for right heart catheterization (RHC). Hemodynamic evaluation showed a pre-capillary PH, with a mean pulmonary arterial pressure (mPAP)

Mailing Address: Rui Plácido

Hospital de Santa Maria, Cardiology. Avenida Professor Egas Moniz. Postal code: 1649-028. Lisboa – Portugal.
E-mail: placidorui@gmail.com



of 45 mmHg, pulmonary capillary wedge pressure of 9 mmHg and pulmonary vascular resistance (PVR) of 12 WU. The right atrial pressure (RAP) was 9 mmHg, cardiac index (CI) was 2 L/min/m², systolic volume index (SVI) was 19 mL/m² and mixed venous oxygen saturation (SvO₂) was 64%.

At first glance, differential diagnosis between pulmonary arterial hypertension (PAH) associated with connective tissue disease versus PH associated with combined pulmonary fibrosis and emphysema was considered. Nevertheless, an FVC/DLCO ratio > 2 pointed to the first hypothesis. Additionally, following an unforeseen conversation with a relative, later confirmed by the patient, it was found a history of cocaine and amphetamine abuse (for eight years, five years ago) and clobenzorex consumption for weight loss (for three years, discontinued six months ago). Accordingly, drug-associated PAH (DPAH) diagnosis was suspected, and initial monotherapy with an endothelin receptor antagonist (ambrisentan) was started, given the presence of pulmonary comorbidities – emphysema and fibrosis. Three months later, the patient was at intermediate-high risk of one-year mortality, according to the simplified four-strata risk-assessment tool^{1,2} and additional PAH medication with a phosphodiesterase-5 inhibitor (tadalafil) was initiated. After six months, the patient was at low risk of one-year mortality. Clinical and laboratory parameters significantly improved: WHO functional

class II, 426 meters in the 6MWT and NT-proBNP of 197 pg/mL. RHC with vasoreactivity test, depicting a low-risk hemodynamic profile (RAP of 4 mmHg, CI of 4 L/min/m², SVI of 48 mL/m² and SvO₂ of 78%) with a mPAP of 31 mmHg, PVR of 5 WU and no acute response to inhaled nitric oxide.

Discussion

PH is a pathophysiological disorder that may be associated with multiple clinical conditions. The management of PH is complex and requires a multifaceted, holistic, and multidisciplinary approach, considering all potential risk factors for the development of intrinsic pulmonary vascular disease along with other mechanisms that lead to PAH, such as parenchymal-interstitial lung disease.³

We report the case of a patient with symptomatic PH associated with SSc whose initial assessment indicated group 3 (clinical classification) PH.³ The patient had a history of drugs/toxins (appetite suppressant, cocaine and methamphetamines) consumption as a contributing factor for intrinsic pulmonary vascular disease, which changed the panorama of the diagnosis of PAH, with important therapeutic and prognostic implications. In fact, the excellent clinical, laboratory and hemodynamic response to therapy confirmed the hypothesis of a case of DPAH in a patient with diffuse SSc and lung disease.⁴

Considering the presence of DPAH, it was deemed necessary to assess acute vasoreactivity during RHC.⁵ If criteria were met,⁶ the clinical scenario may change towards a favorable and sustained clinical and hemodynamic response with oral calcium channel blockers. However, the response to inhaled nitric oxide was negative in our patient and the therapeutic strategy with dual pulmonary vasodilator therapy remained unchanged.

Conclusion

The etiology of PAH is often challenging, in which a detailed clinical history is of utmost importance. The integration of all possible contributing factors for the development of PH with the global clinical picture, highlights the complexity of intrinsic pulmonary vascular disease, the true target of pulmonary vasodilator therapy.

Author Contributions

Conception and design of the research and critical revision of the manuscript for intellectual content: António OS, António MS, Resende CL, Guimarães T, Cazeiro

D, Pereira YS, Pinto FJ, Plácido R; acquisition of data: António OS, António MS, Guimarães T, Pereira YS, Plácido R; analysis and interpretation of the data: António OS, Resende CL, Cazeiro D, Plácido R; writing of the manuscript: António OS, António MS, Resende CL, Guimarães T, Cazeiro D, Pereira YS, Plácido R.

Potential Conflict of Interest

No potential conflict of interest relevant to this article was reported.

Sources of Funding

There were no external funding sources for this study.

Study Association

This study is not associated with any thesis or dissertation work.

Ethics Approval and Consent to Participate

This article does not contain any studies with human participants or animals performed by any of the authors.

References

1. Hoeper MM, Pausch C, Olsson KM, Huscher D, Pittrow D, Grünig E, et al. COMPERA 2.0: A Refined Four-Stratum Risk Assessment Model for Pulmonary Arterial Hypertension. *Eur Respir J*. 2022;60(1):2102311. doi: 10.1183/13993003.02311-2021.
2. Boucly A, Weatherald J, Savale L, Groote P, Cottin V, Prévot G, et al. External Validation of a Refined Four-Stratum Risk Assessment Score from the French Pulmonary Hypertension Registry. *Eur Respir J*. 2022;59(6):2102419. doi: 10.1183/13993003.02419-2021.
3. Humbert M, Kovacs G, Hoeper MM, Badagliacca R, Berger RMF, Brida M, et al. 2022 ESC/ERS Guidelines for the Diagnosis and Treatment of Pulmonary Hypertension. *Eur Heart J*. 2022;43(38):3618-731. doi: 10.1093/eurheartj/ehac237.
4. Launay D, Montani D, Hassoun PM, Cottin V, Le Pavec J, Clerson P, et al. Clinical Phenotypes and Survival of Pre-Capillary Pulmonary Hypertension in Systemic Sclerosis. *PLoS One*. 2018;13(5):e0197112. doi: 10.1371/journal.pone.0197112.
5. Sun Y, Li Y, Meng X, Jiang R, Zhao Q, Wang L, et al. Acute Vasoreactivity Testing Predicts Outcome of Idiopathic Pulmonary Arterial Hypertension Patients with a Negative Acute Response. *Ann Transl Med*. 2020;8(24):1650. doi: 10.21037/atm-20-7339.
6. Sitbon O, Humbert M, Jaïs X, Ioos V, Hamid AM, Provencher S, et al. Long-Term Response to Calcium Channel Blockers in Idiopathic Pulmonary Arterial Hypertension. *Circulation*. 2005;111(23):3105-11. doi: 10.1161/CIRCULATIONAHA.104.488486.

